



HEALCERION

Image Gallery

SONON

Smart Healthcare for all

Healcerion Co., Ltd.

Address: 804ho, 38-21, Digital-ro 31-gil,
Guro-Gu, Seoul, 08376 Korea
www.healcerion.com Tel: +82.70.7569.6326,
E-mail: info@healcerion.com
© 2019 Copyright. All Rights Reserved.

Musculoskeletal

MSK : Shoulder

clinicalimage
1

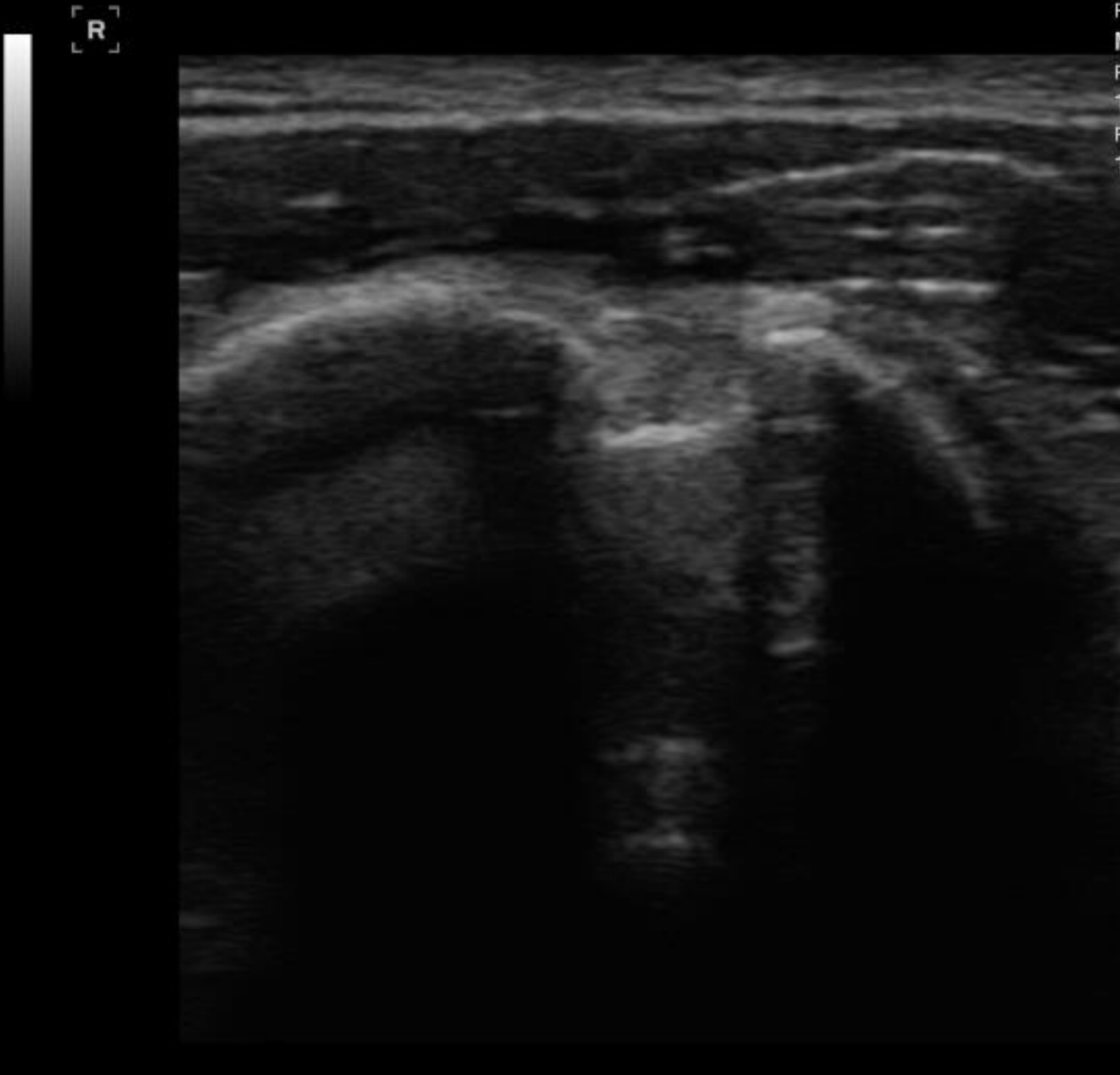
10/19/2017 14:40:23
q | -
MI:0.73 / TIB:0.28

clinicalimage
1

10/19/2017 14:44:23
q | -
MI:0.73 / TIB:0.28

99%

98%

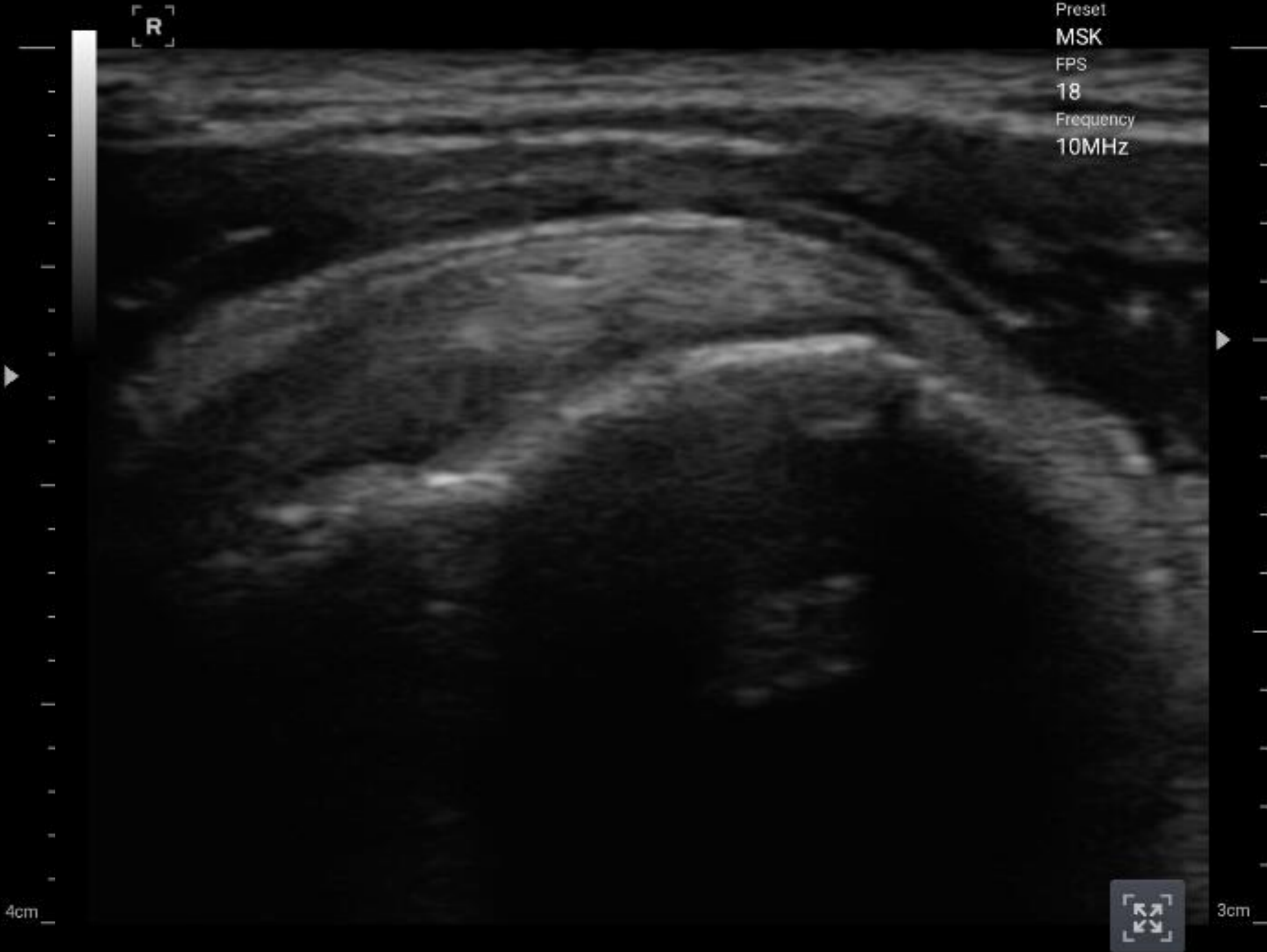


Preset
MSK
FPS
18
Frequency
10MHz



4cm

Biceps Tendon



Preset
MSK
FPS
18
Frequency
10MHz



3cm

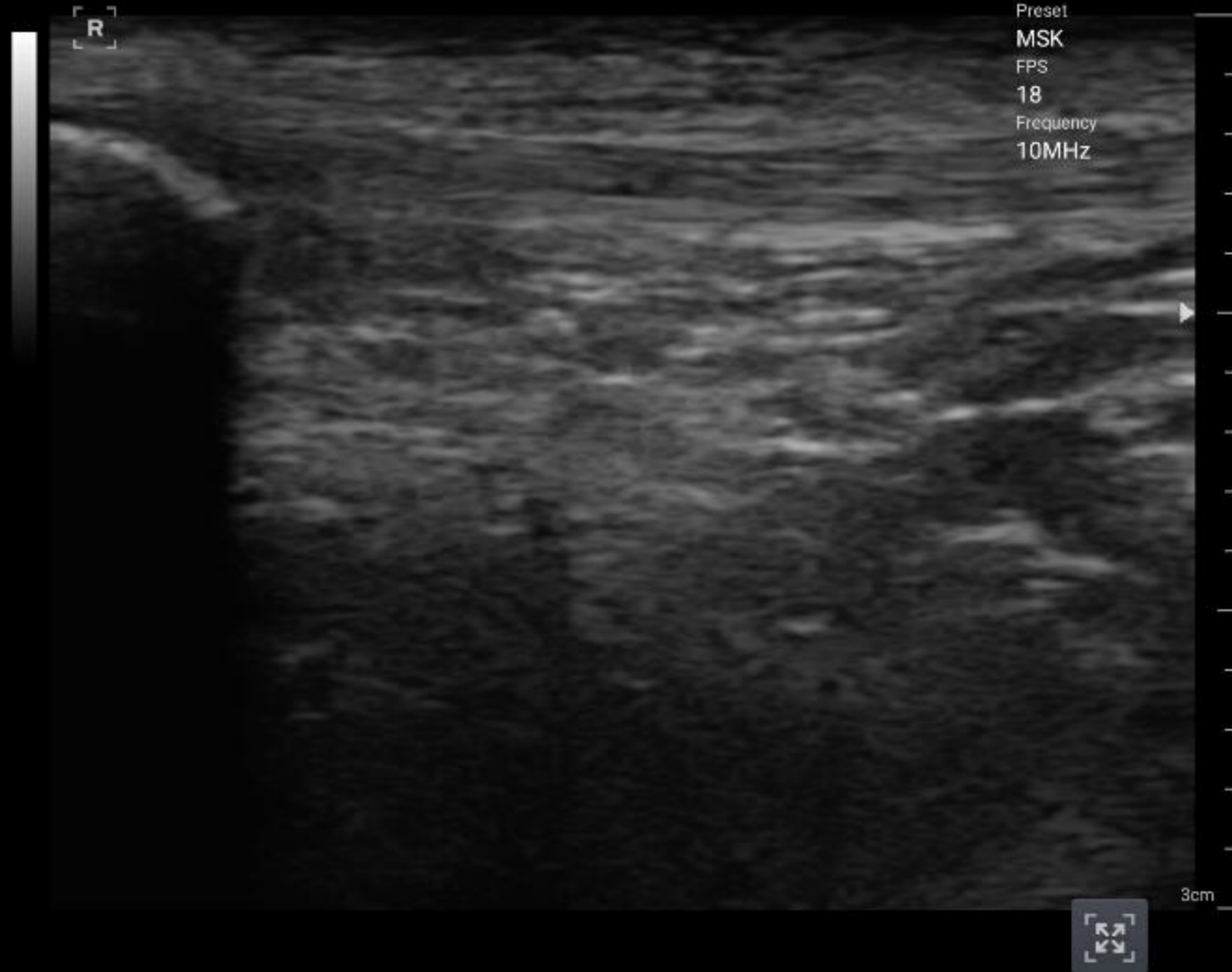
Supraspinatus tendon

MSK : Knee

clinicalimage
1

10/19/2017 14:51:22
q | -
MI:0.73 / TIB:0.28

95%

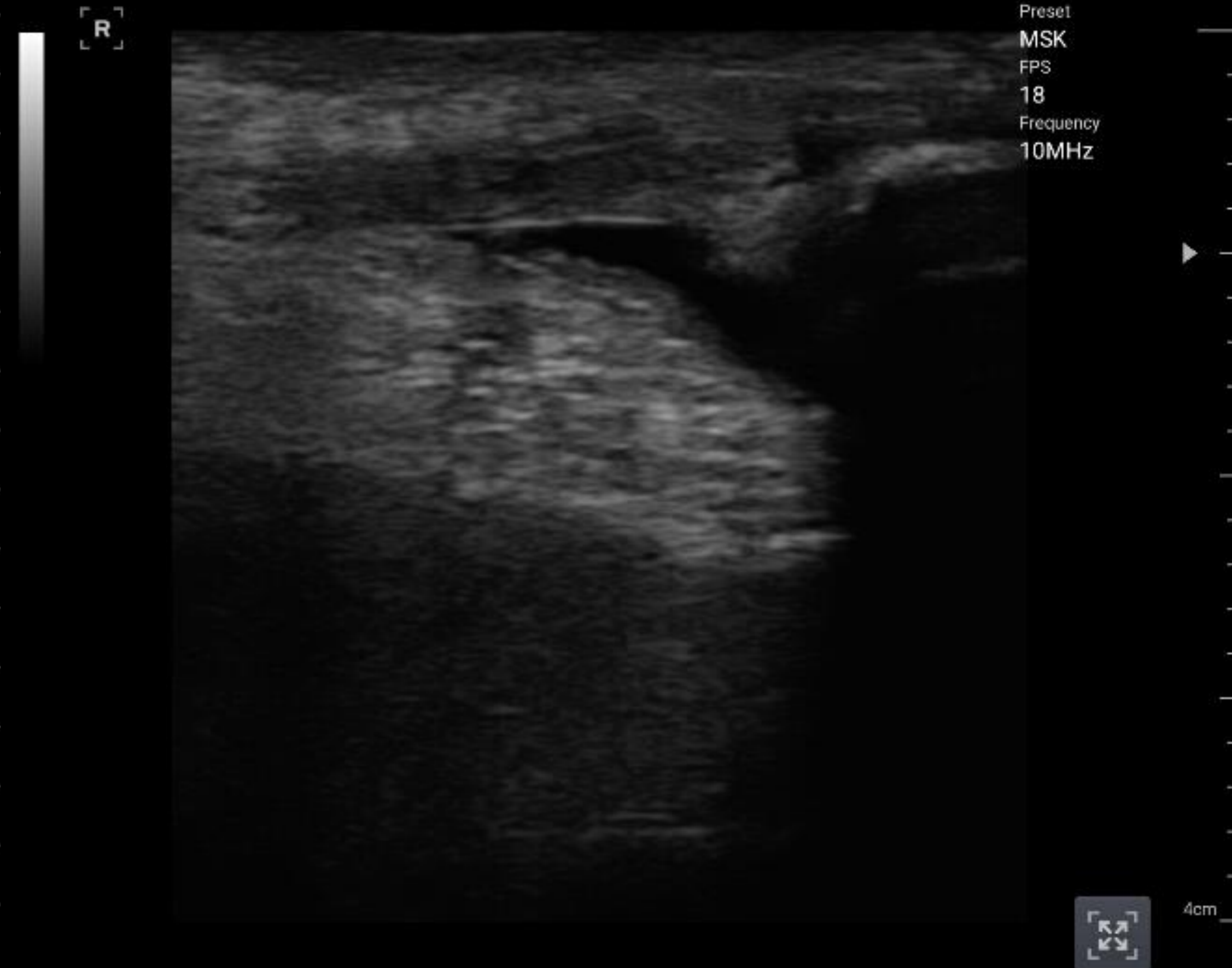


patellar tendon

clinicalimage
1

10/19/2017 14:49:23
q | -
MI:0.73 / TIB:0.28

96%



Suprapatellar bursitis

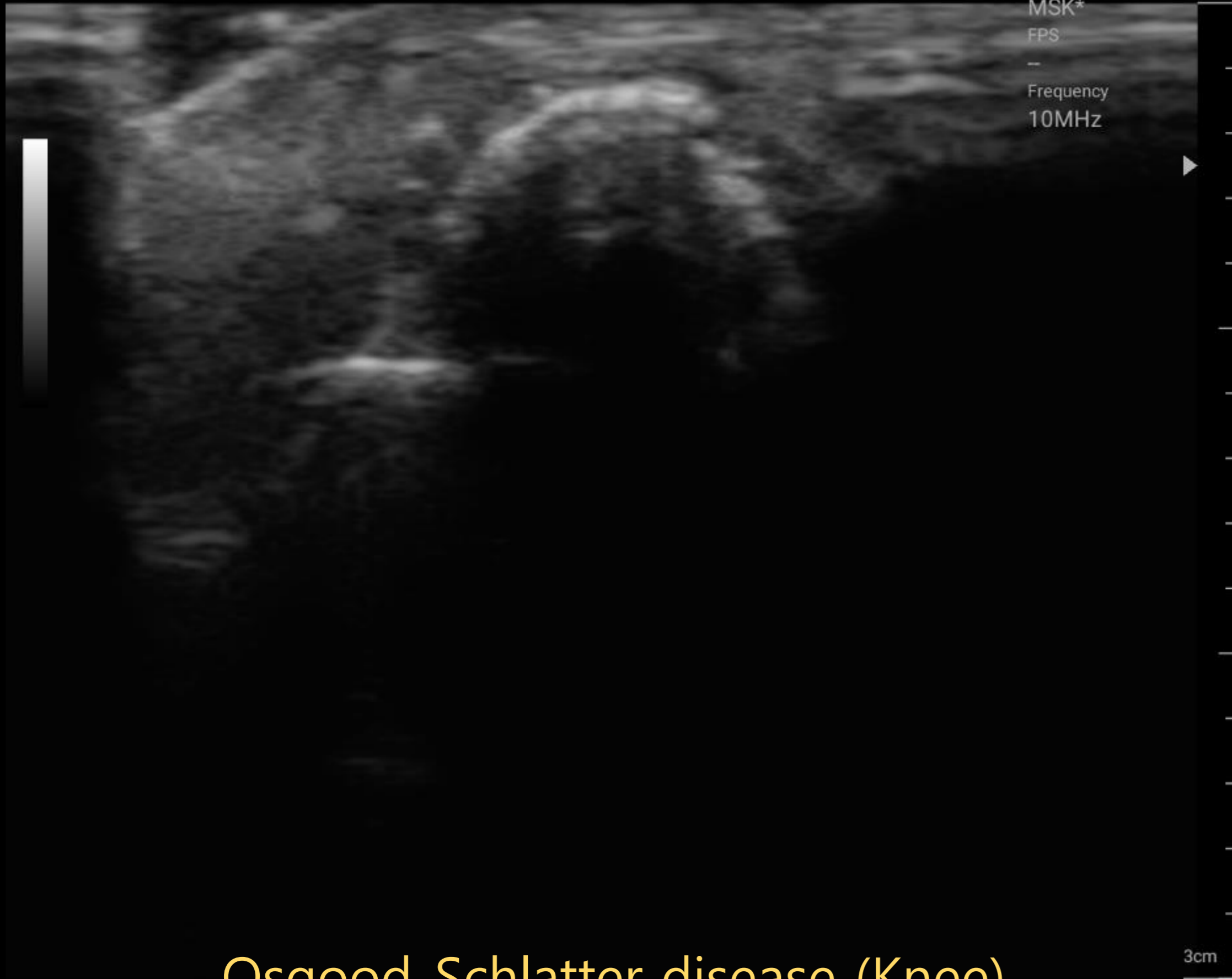
MSK : Knee



01/10/2019 09:45:08
q | -
MI:0.73 / TIB:0.28

96%

R



Osgood-Schlatter disease (Knee)

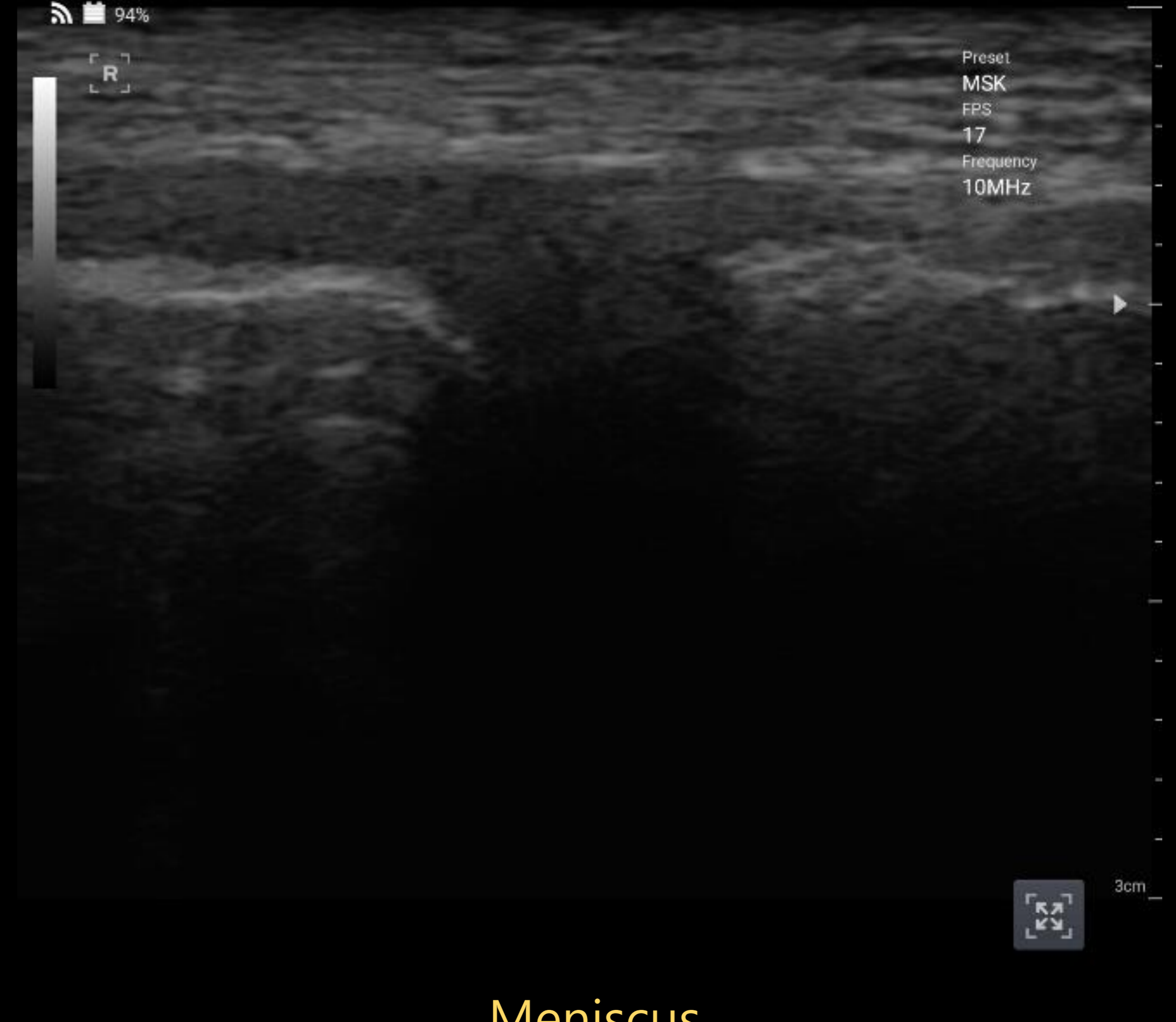

clinicalimage
1

10/19/2017 14:53:06
q | -
MI:0.73 / TIB:0.28

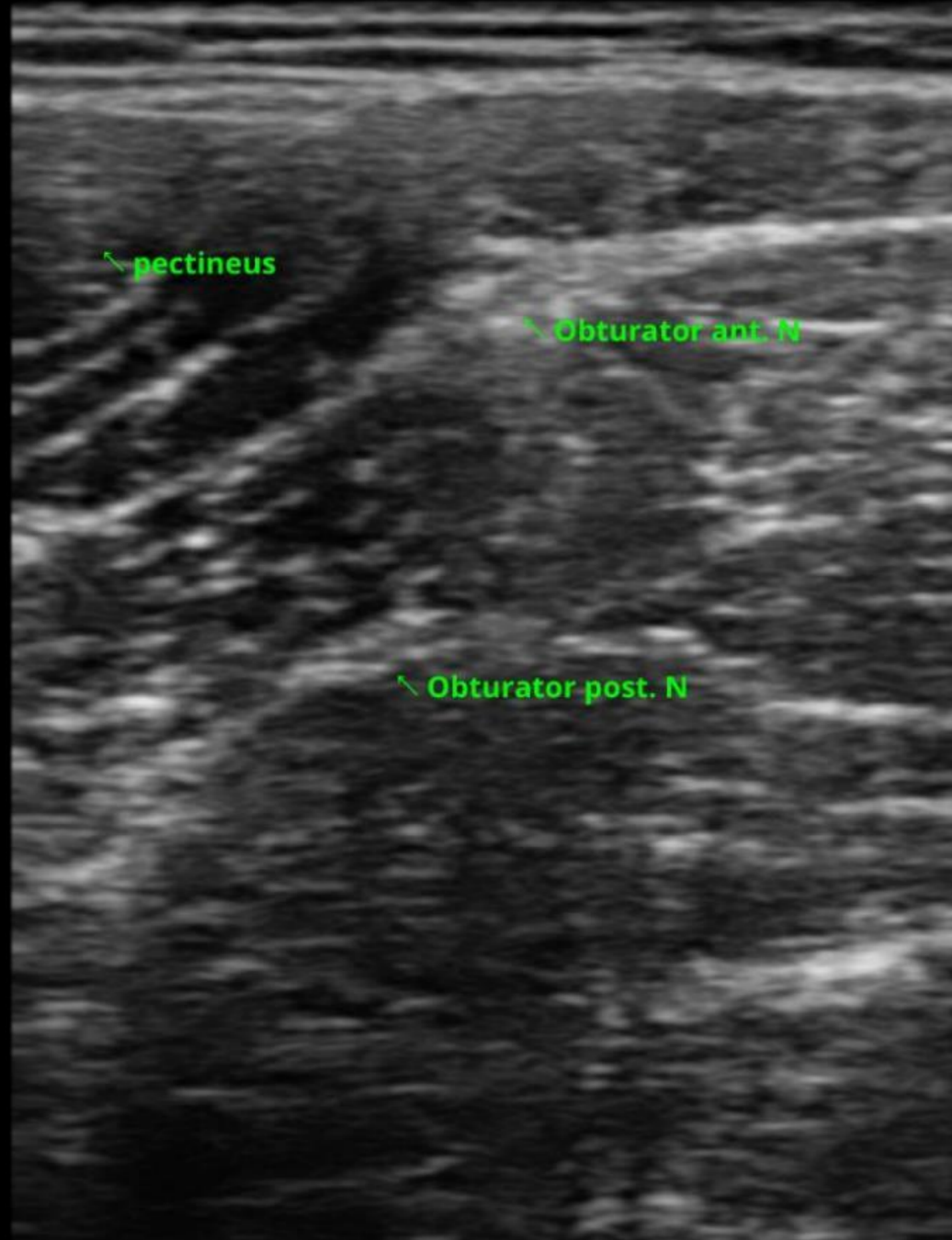
94%

R



Meniscus

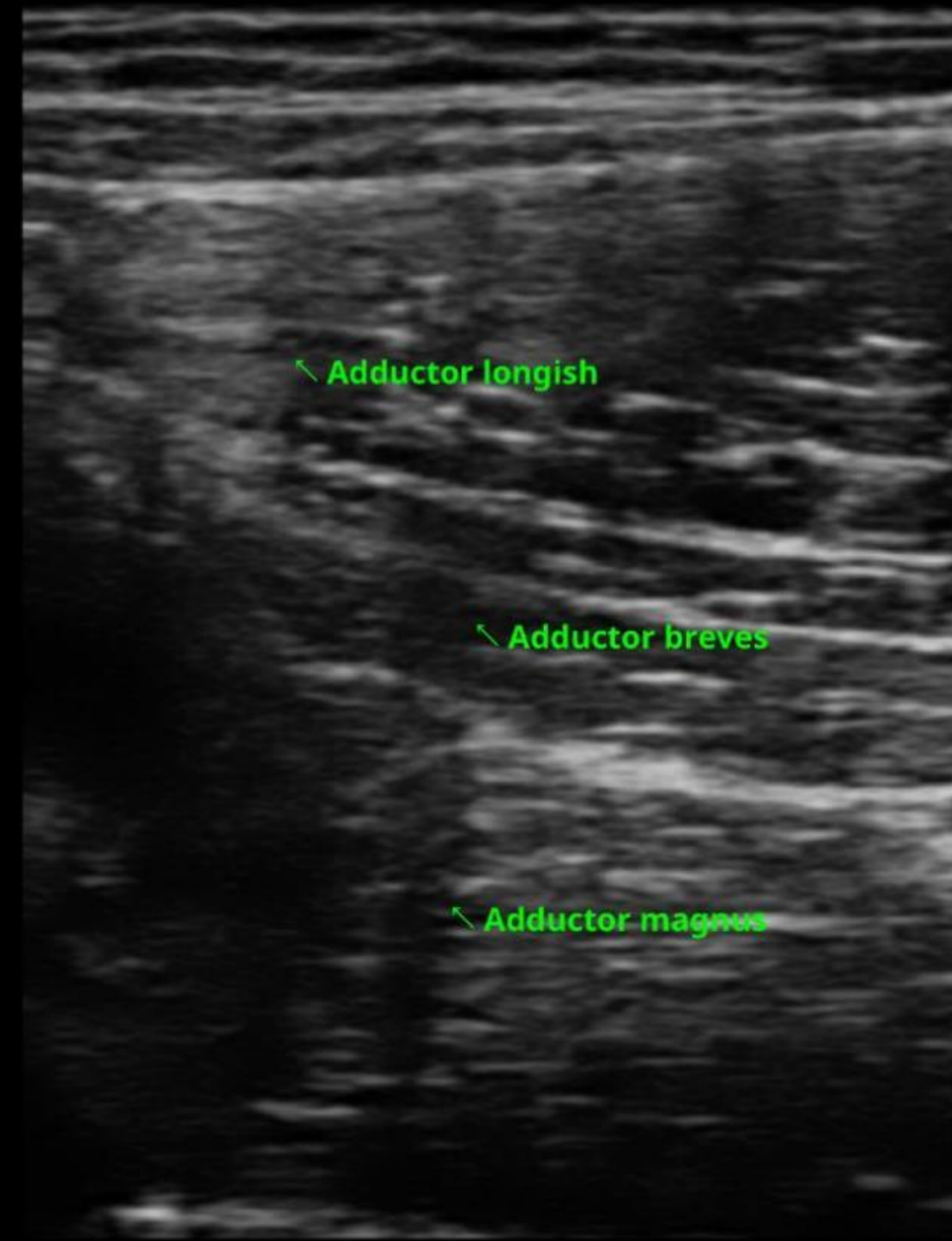
MSK : Thigh



Obturator nerve

2018/09/06 01:26:52 PM
Unknown | hc
MI:0.82 / TIB:0.33

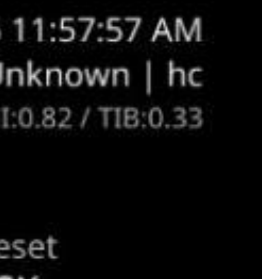
Preset
MSK
FPS
21
Frequency
10Mhz



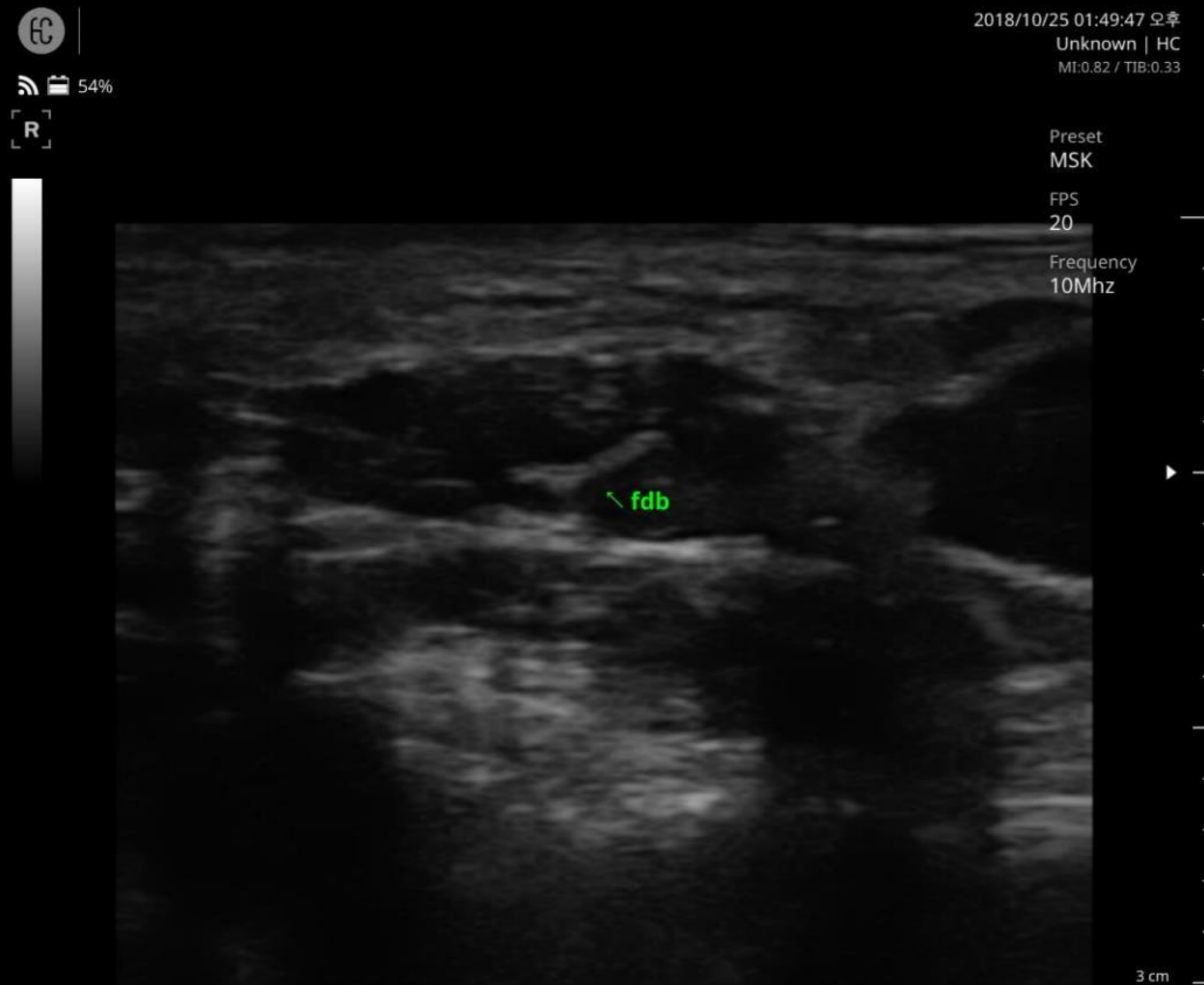Abductor Group

2018/09/06 11:57:57 AM
Unknown | hc
MI:0.82 / TIB:0.33

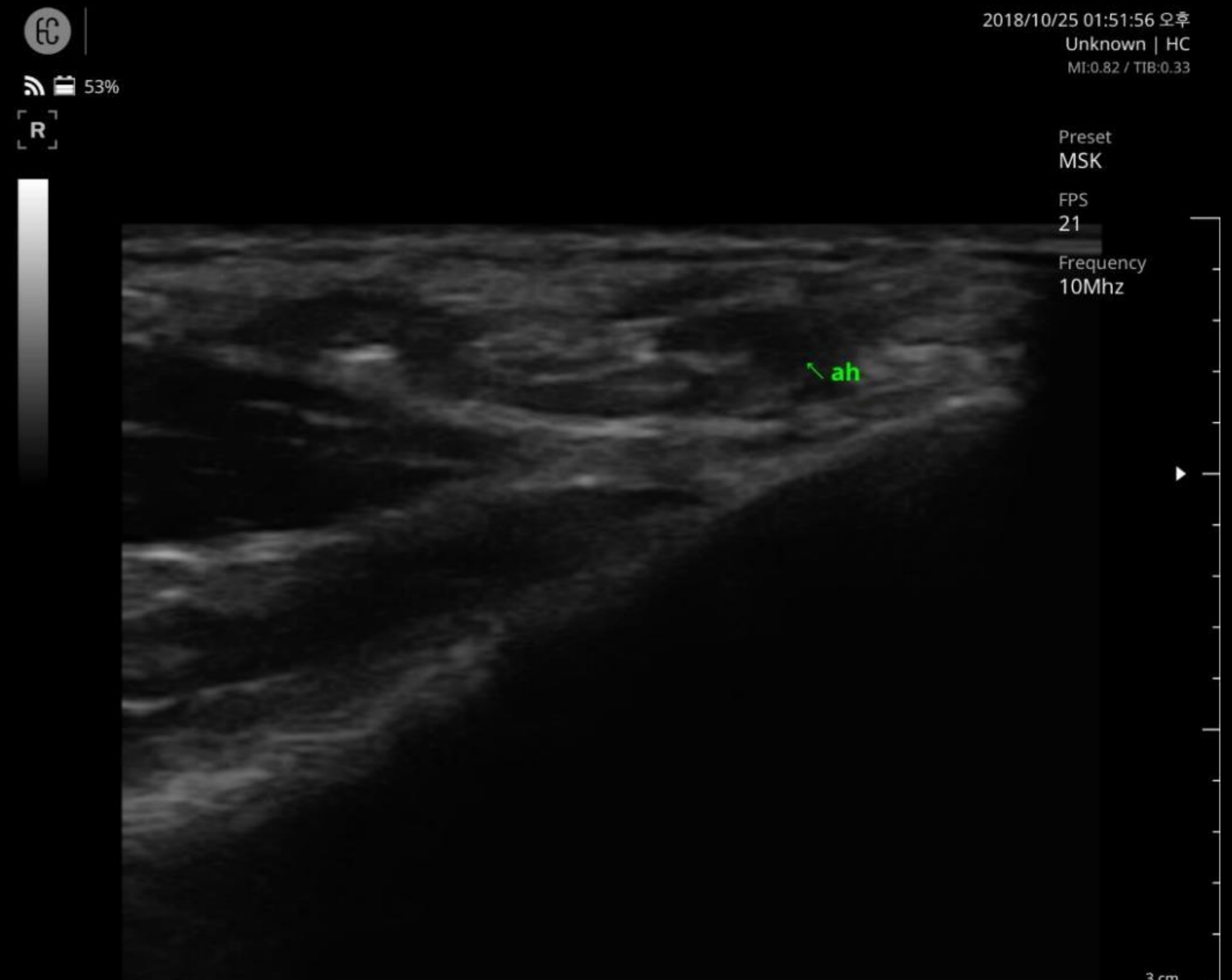Preset
MSK
FPS
21
Frequency
10Mhz



MSK : Foot



Flexor digitorum brevis muscle



Abductor hallucis muscle

MSK : Wrist

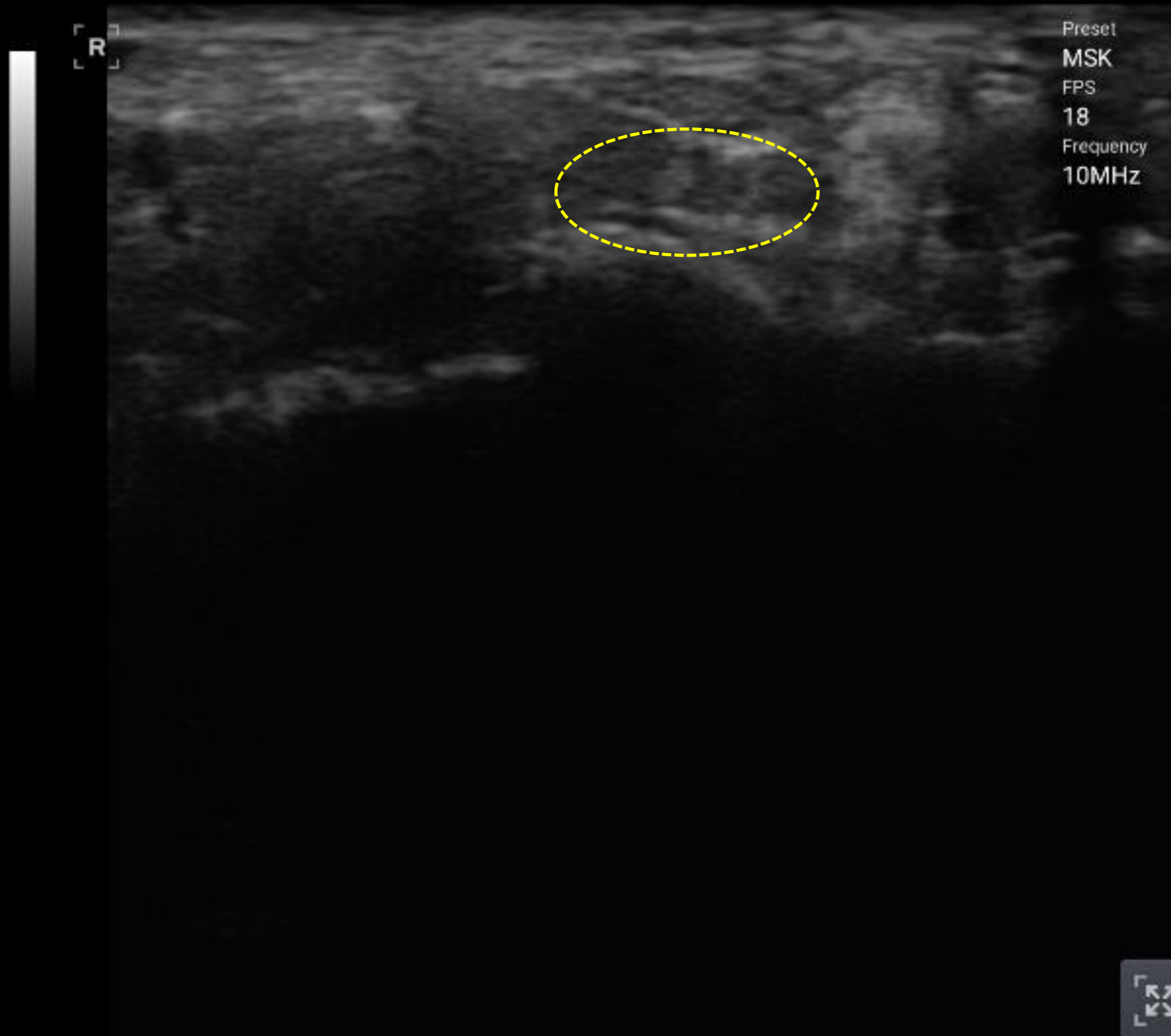
clinicalimage2
2

10/19/2017 15:17:05
MI:0.73 / TIB:0.28

67%

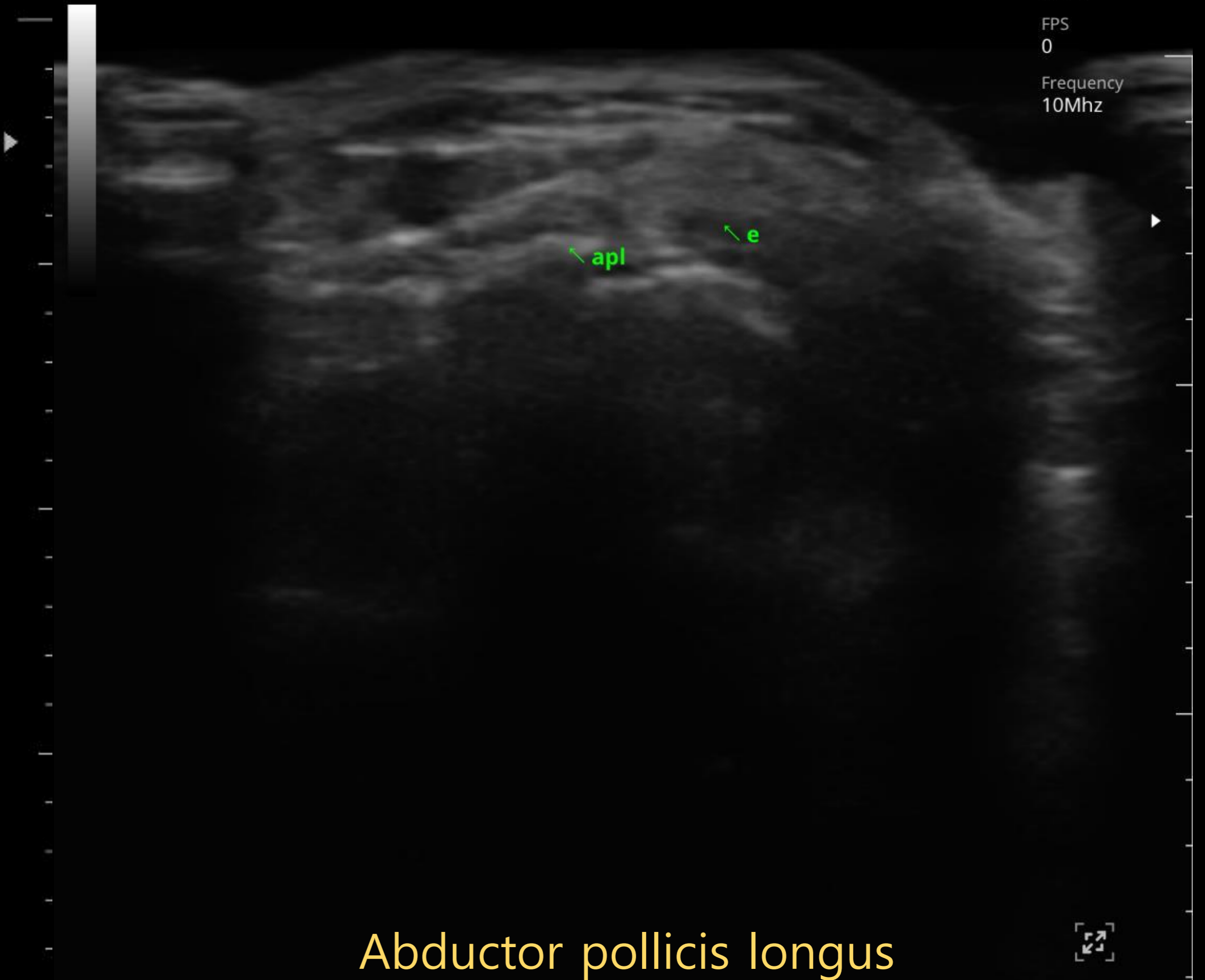
2018/10/25 01:20:27 오후
Unknown | HC
MI:0.00 / TIB:0.00

85%



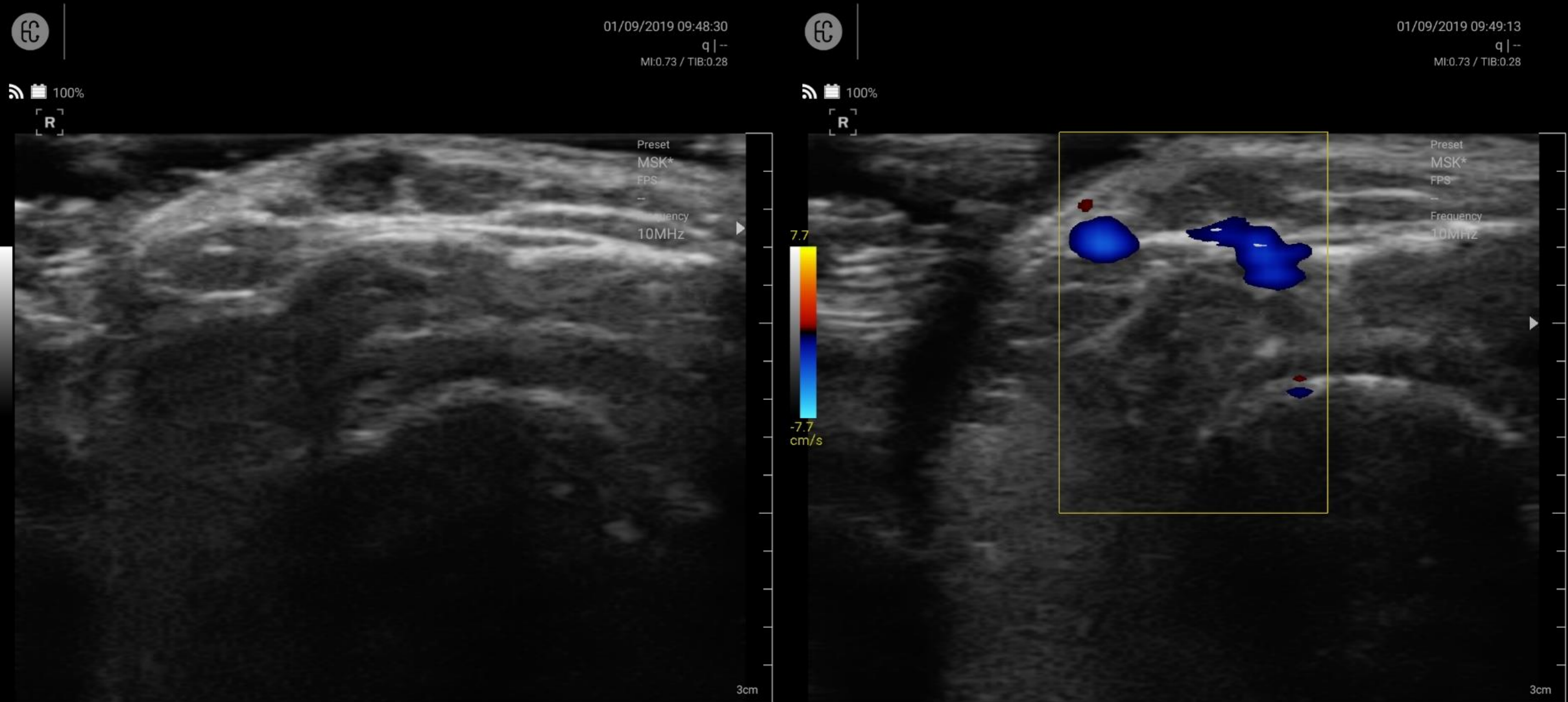
Median nerve

R



Abductor pollicis longus
Extensor pollicis brevis

MSK : Skin



Hemangioma

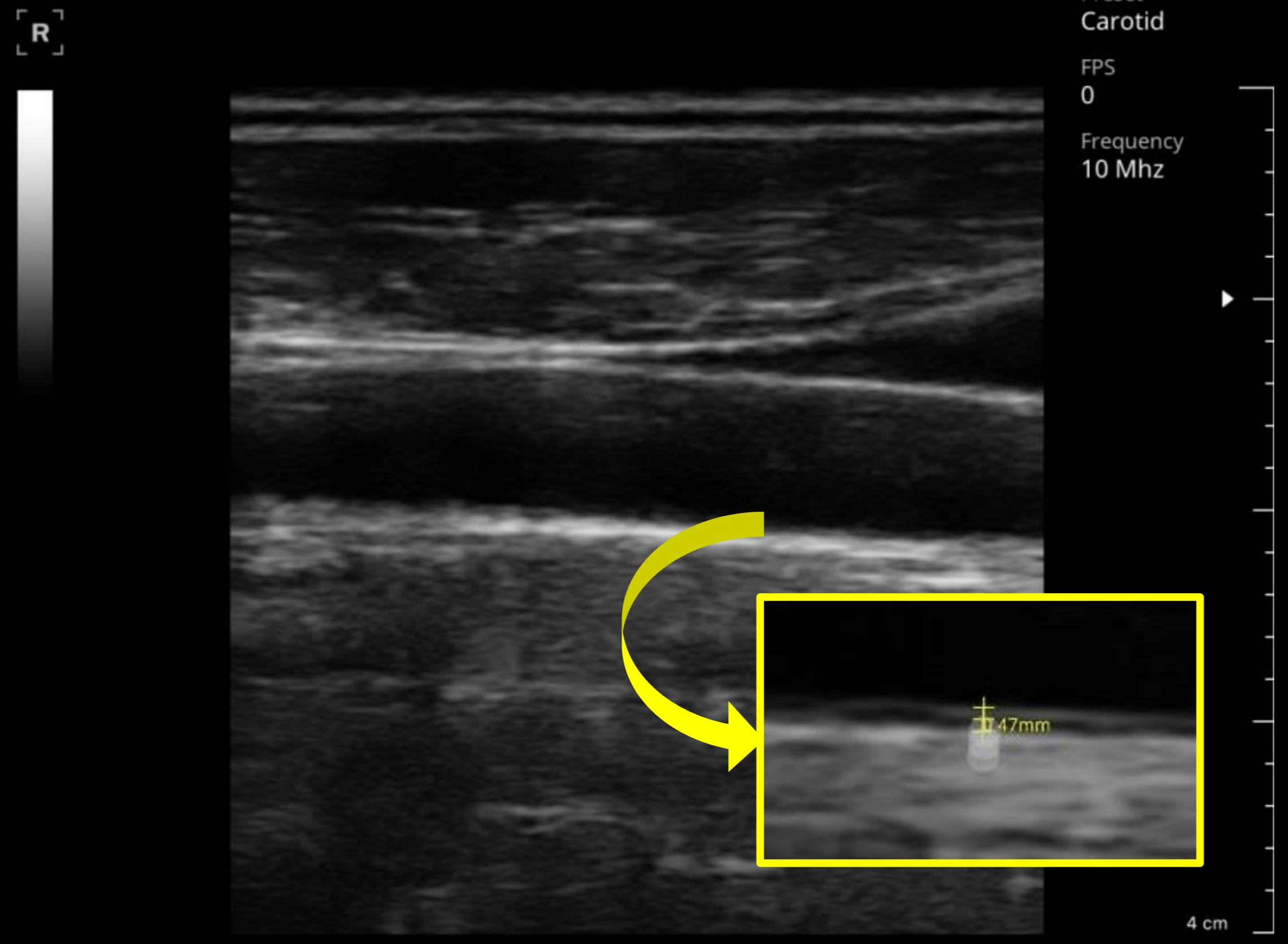
Hemangioma with Color Flow

Vascular

Carotid

170108

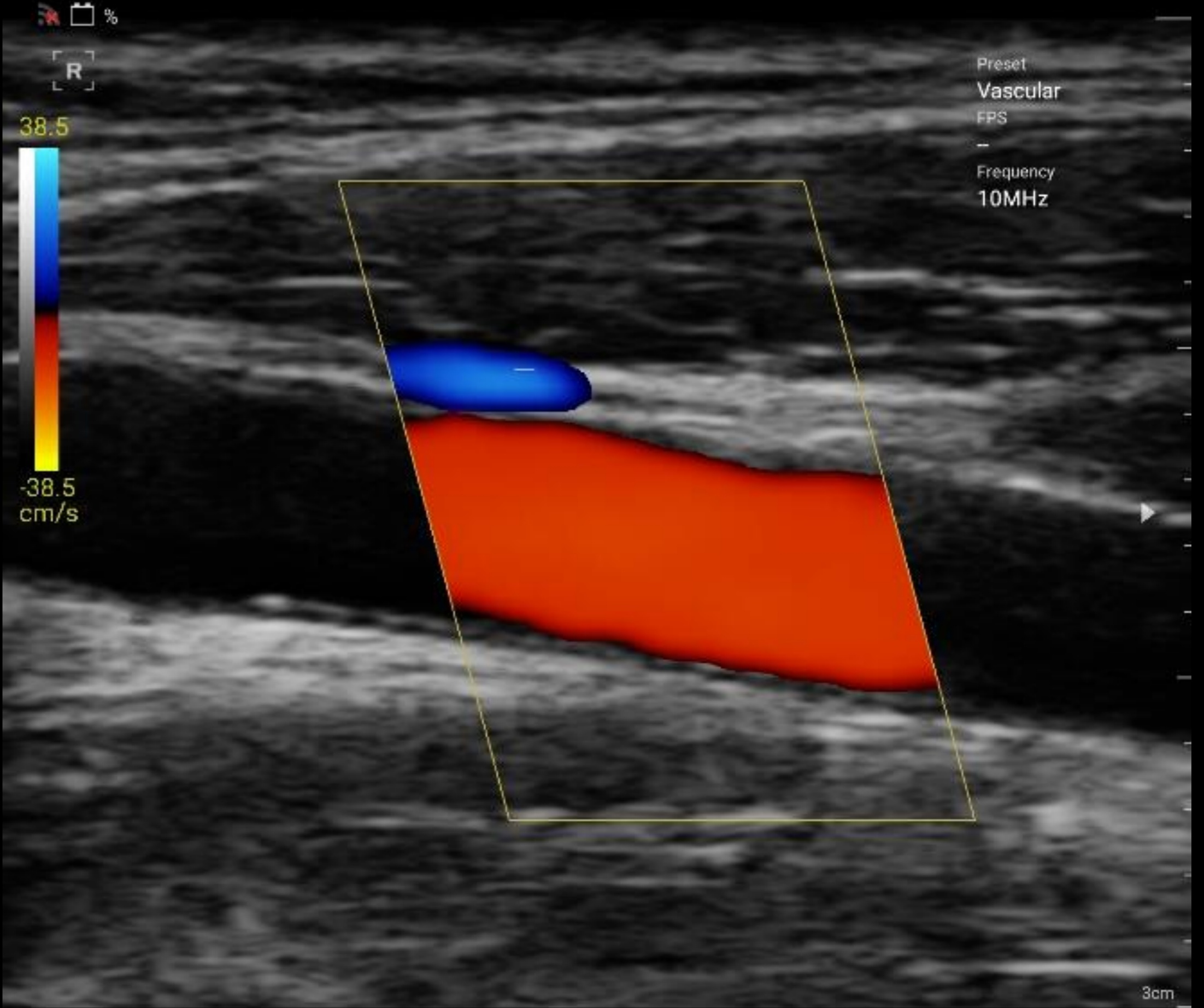01/09/2017 12:23:31 오전
Healcerion | Erika
MI:0.82 / TIB:0.33



Carotid IMT

clinicalimage2
2

10/19/2017 15:10:22
MI:0.73 / TIB:0.28



Common carotid artery

Lower extremity

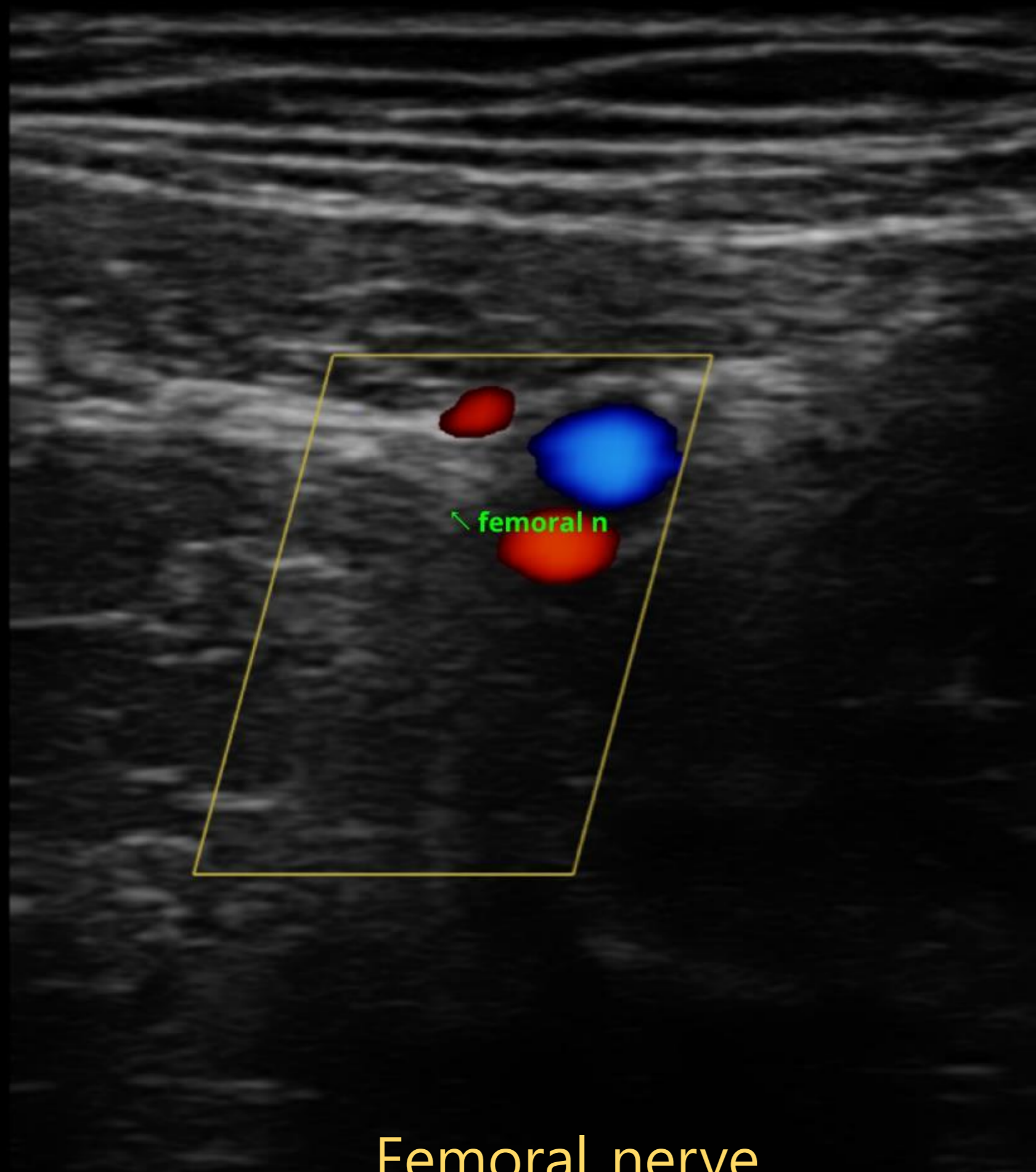


62%

R
19.3



-19.3
cm/s



Femoral nerve

2018/09/06 12:15:44 PM
Unknown | hc
MI:0.82 / TIB:0.33



62%

Preset
MSK
FPS
0
Frequency
10Mhz

R
7.7

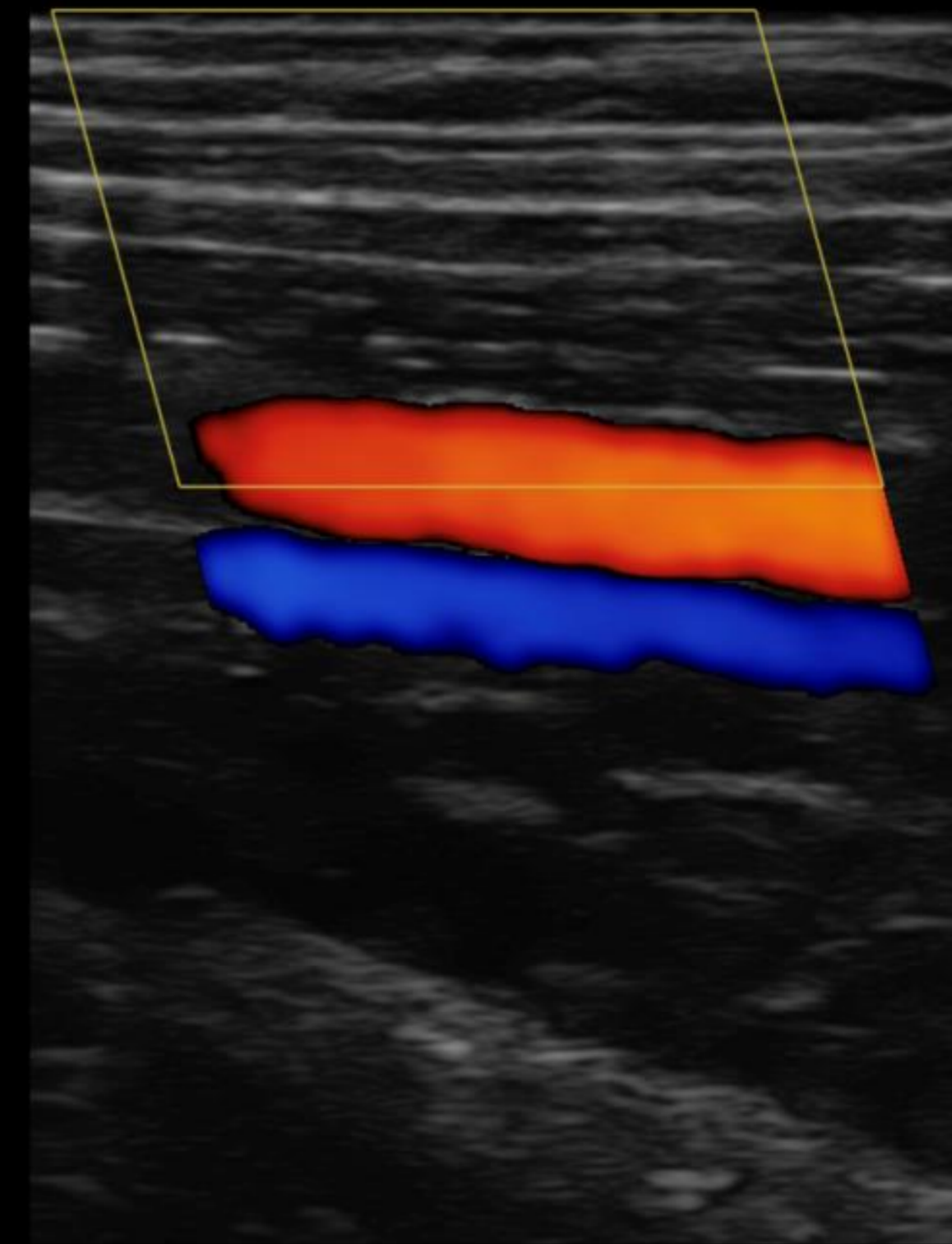


-7.7
cm/s



01/09/2017 12:46:25 오전
Healcerion | Erika
MI:0.82 / TIB:0.33

Preset
Vascular
FPS
0
Frequency
10 Mhz



5 cm

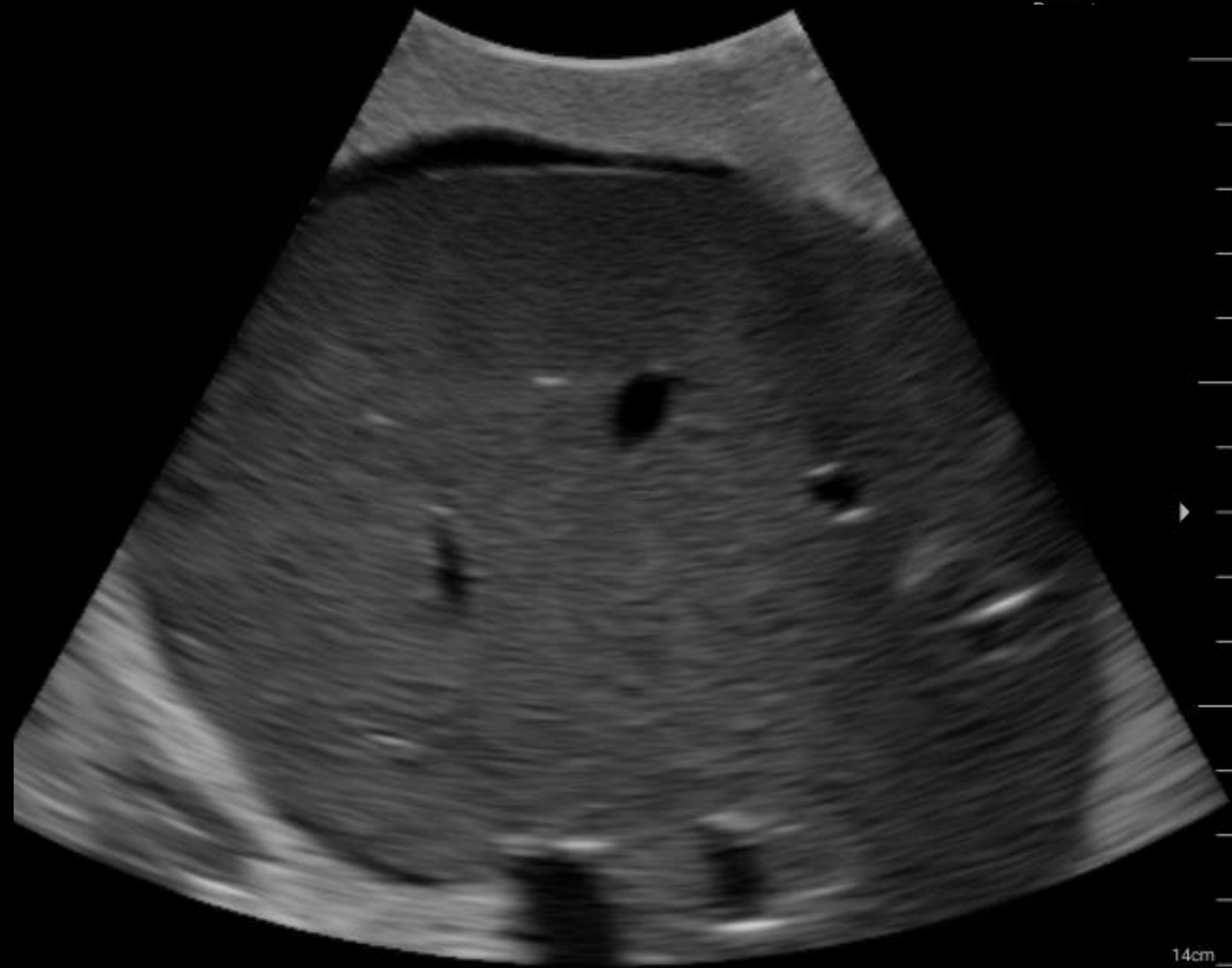
Trauma scan

FAST scan

300c_new
300c_new

96%

R



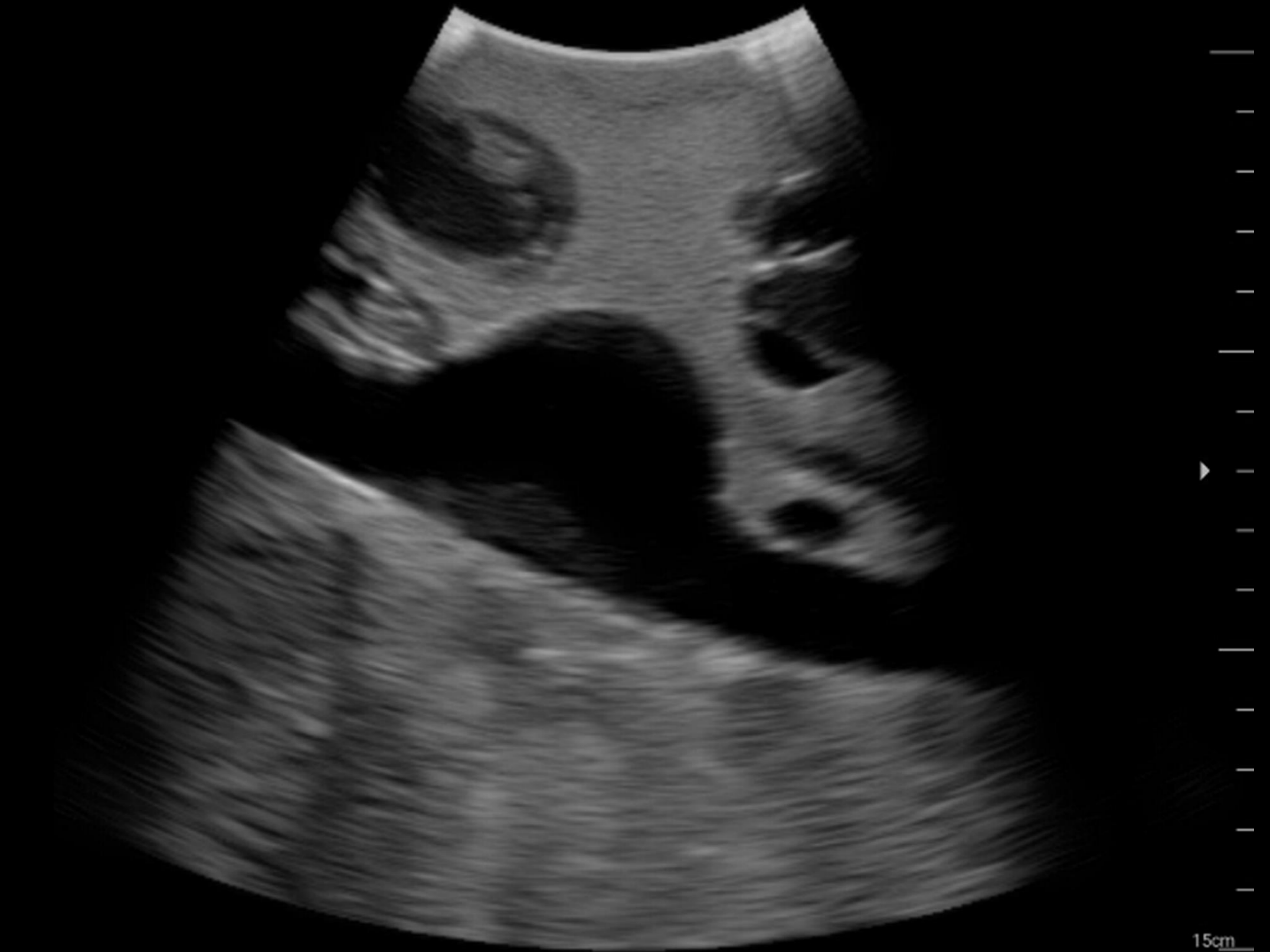Internal bleeding

2017/11/03 02:34:23 오후
HC | Unknown
MI:0.48 / TIB:0.20

300c_new
300c_new

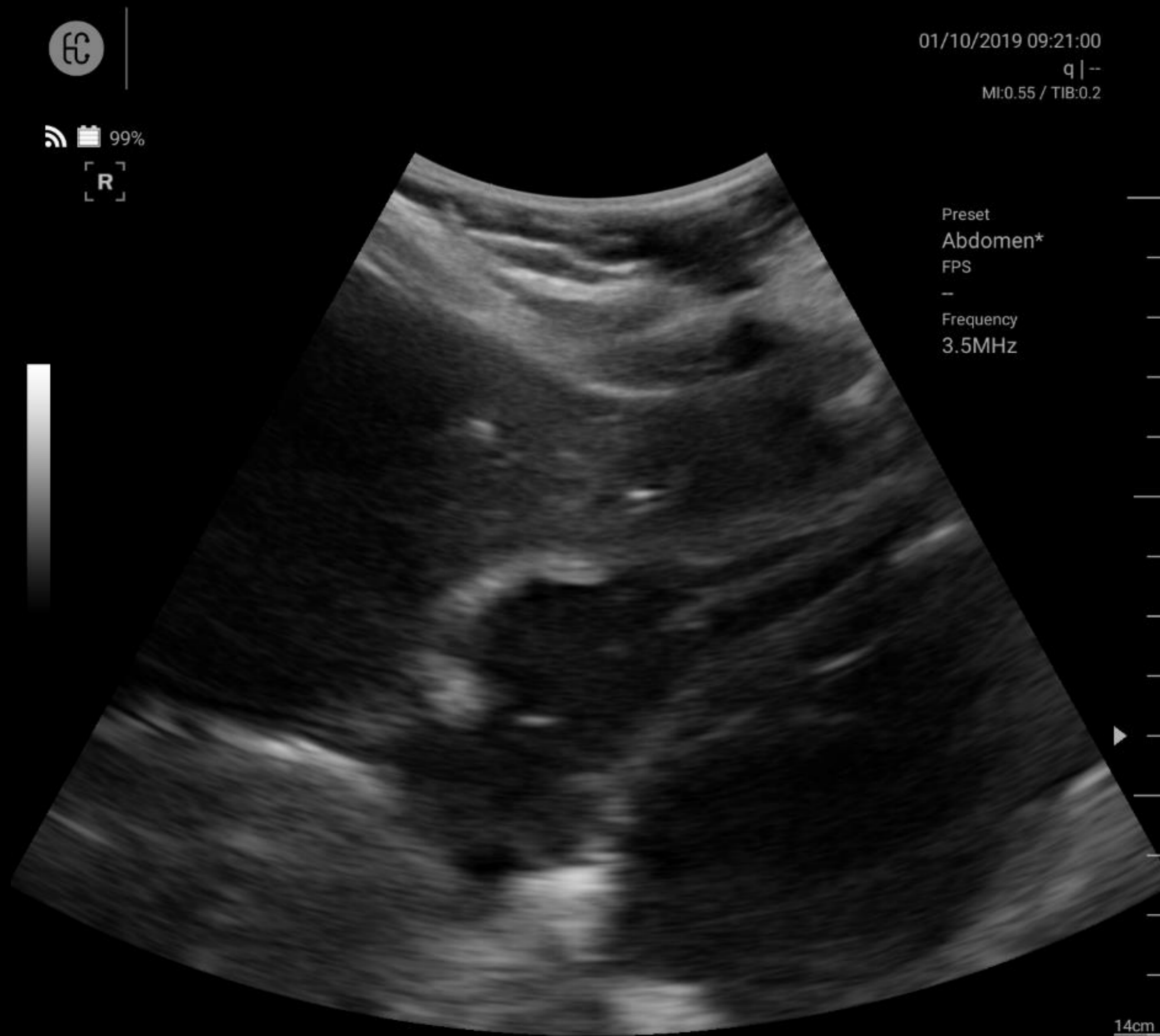
96%

R

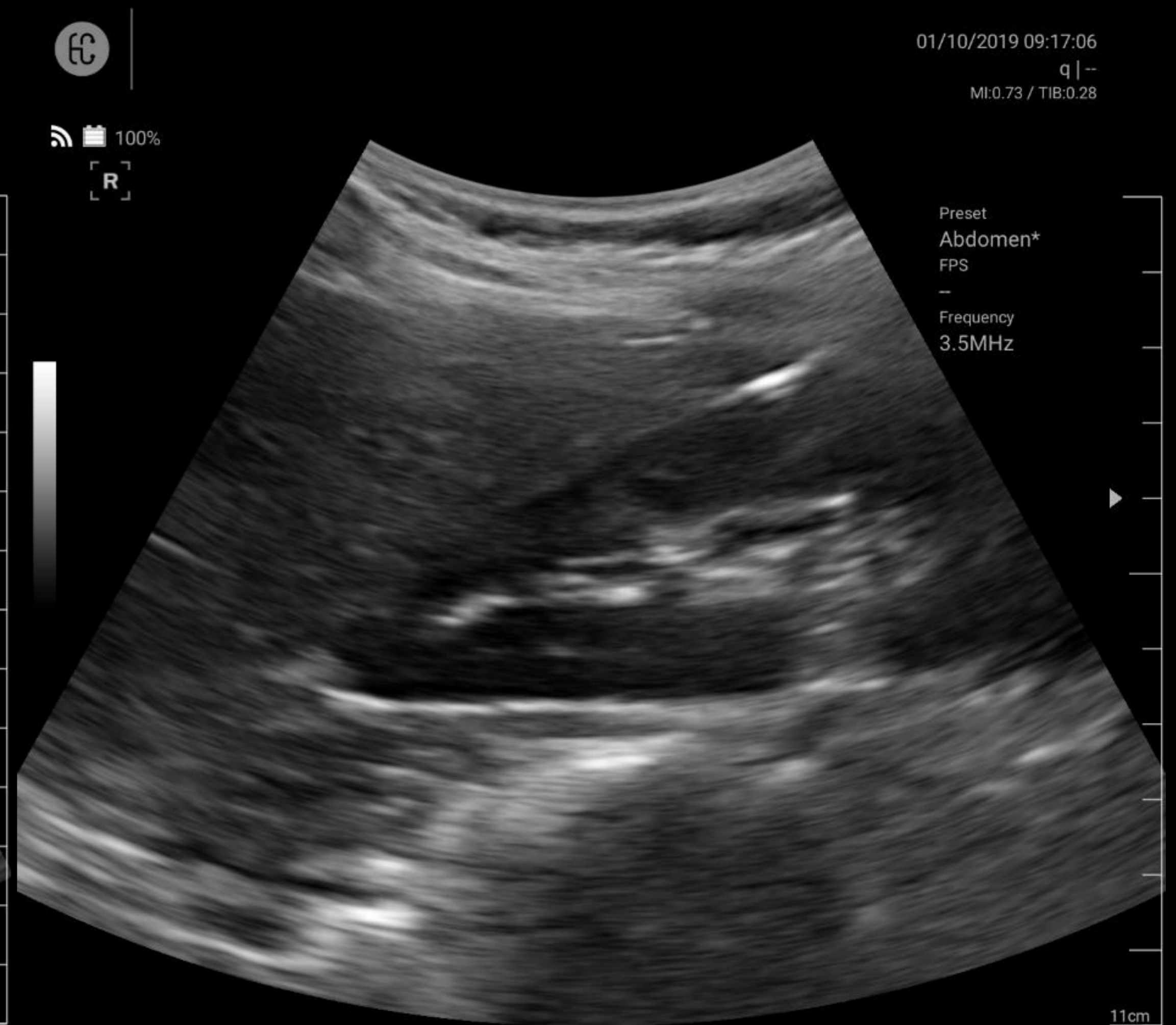


Aorta aneurysm

FAST scan

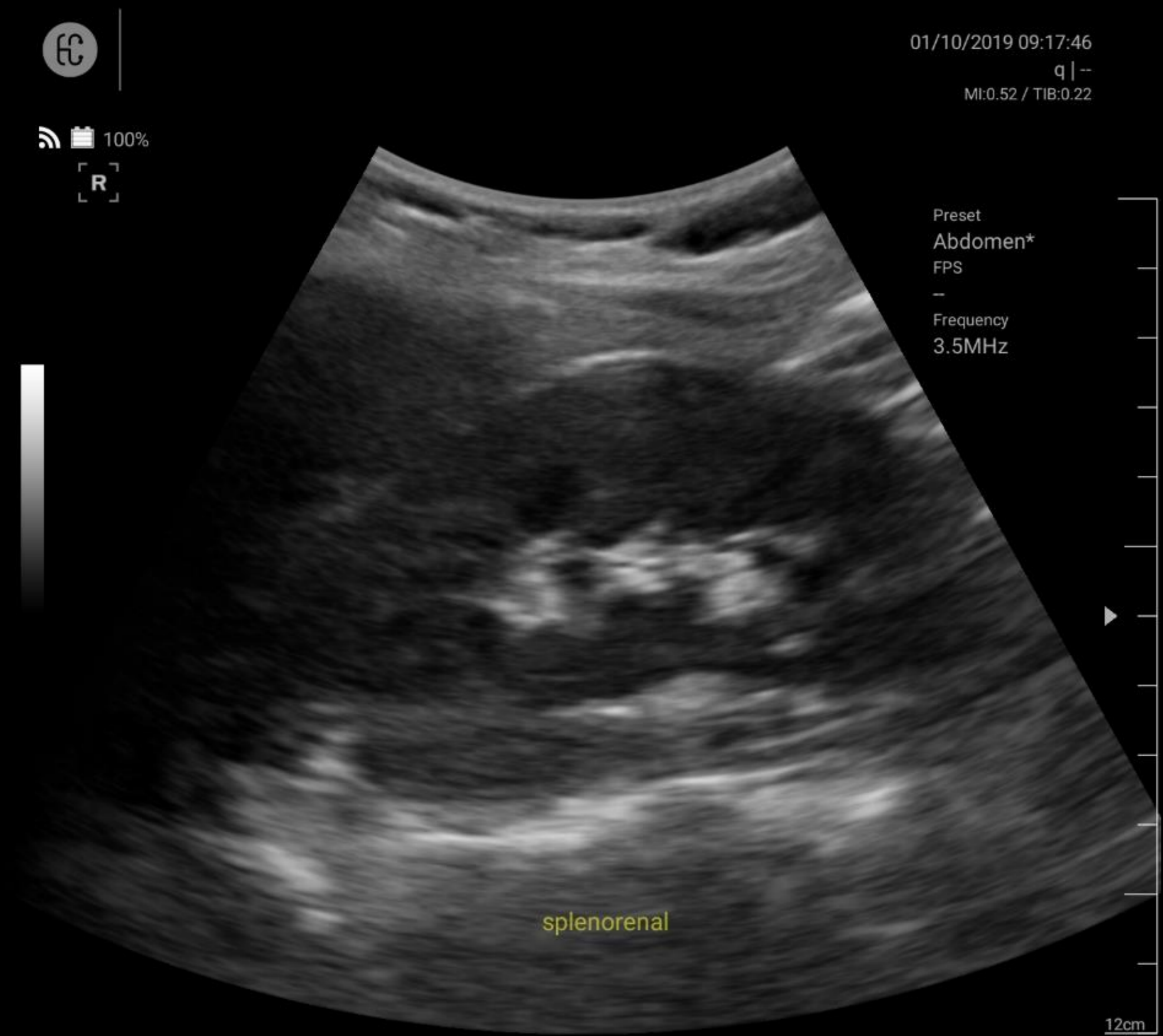


Pericardial view : pericardium

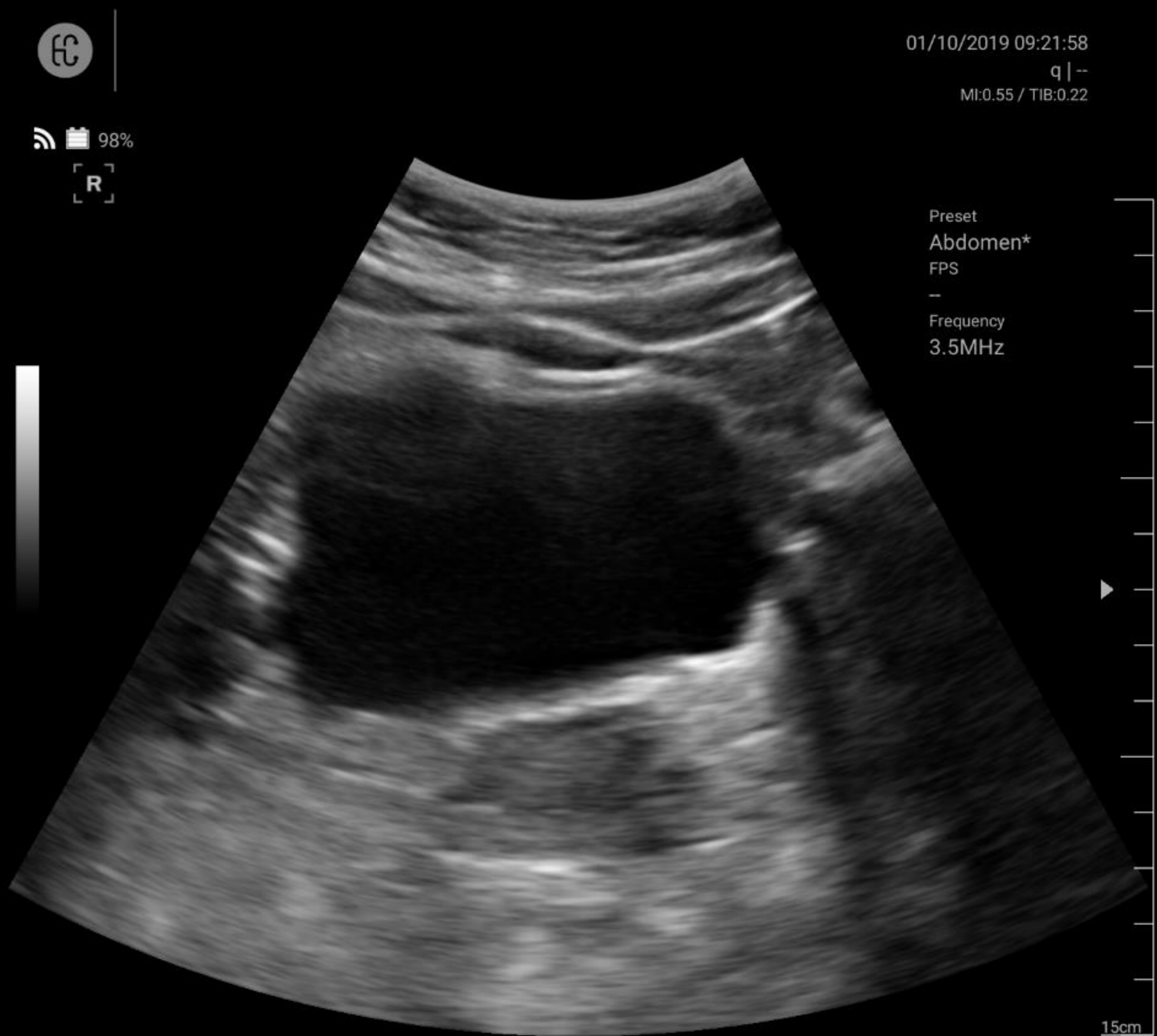


Right flank view : Morison pouch

FAST scan



Left flank view : splenorenal junction



Pelvic view : Douglas pouch

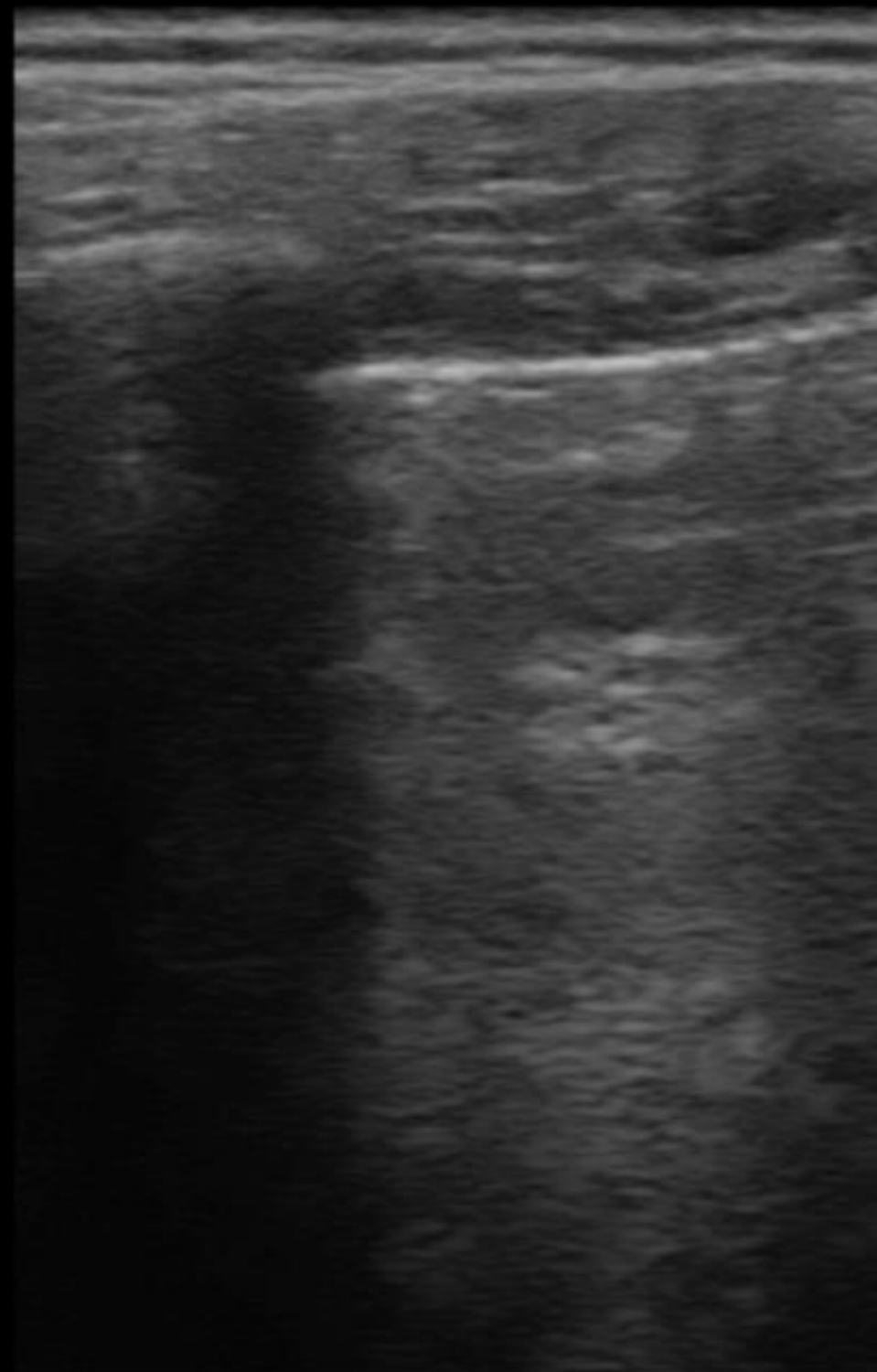
Lung



20170108

01/09/2017 12:38:41 오전
Healcerion | Erika
MI:0.73 / TIB:0.28

R



Preset
Lung

FPS
0

Frequency
10 Mhz

6 cm

Anterior pleural view : Lung

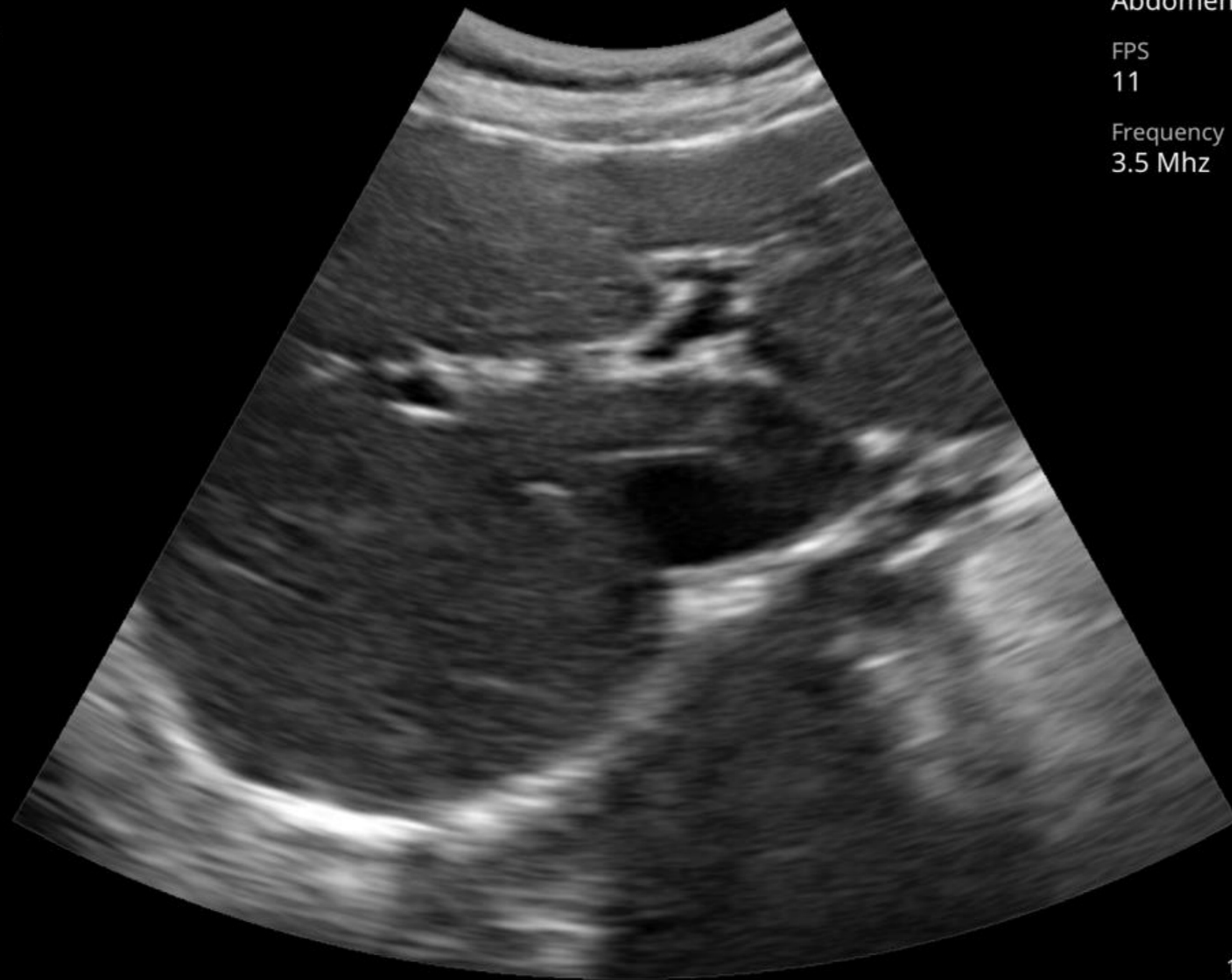
General image

Abdomen : Liver

300c_new
300c_new

96%

R



Portal vein portion

2017/11/03 02:32:46 오후
HC | Unknown
MI:0.48 / TIB:0.20

Preset
Abdomen

FPS
11

Frequency
3.5 Mhz

R



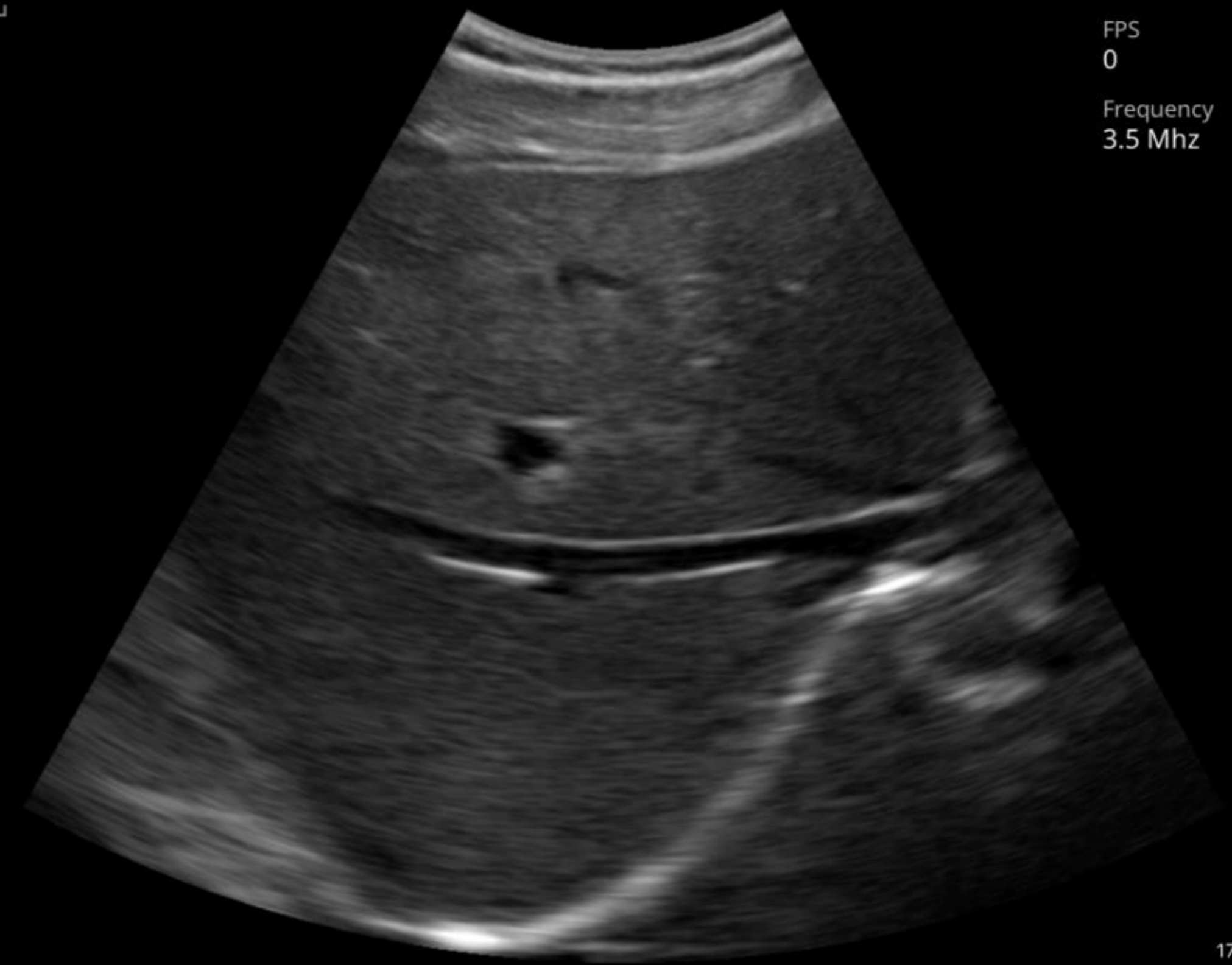
20170108

01/08/2017 10:42:07 오후
Healcerion | Erika
MI:0.48 / TIB:0.20

Preset
Abdomen

FPS
0

Frequency
3.5 Mhz



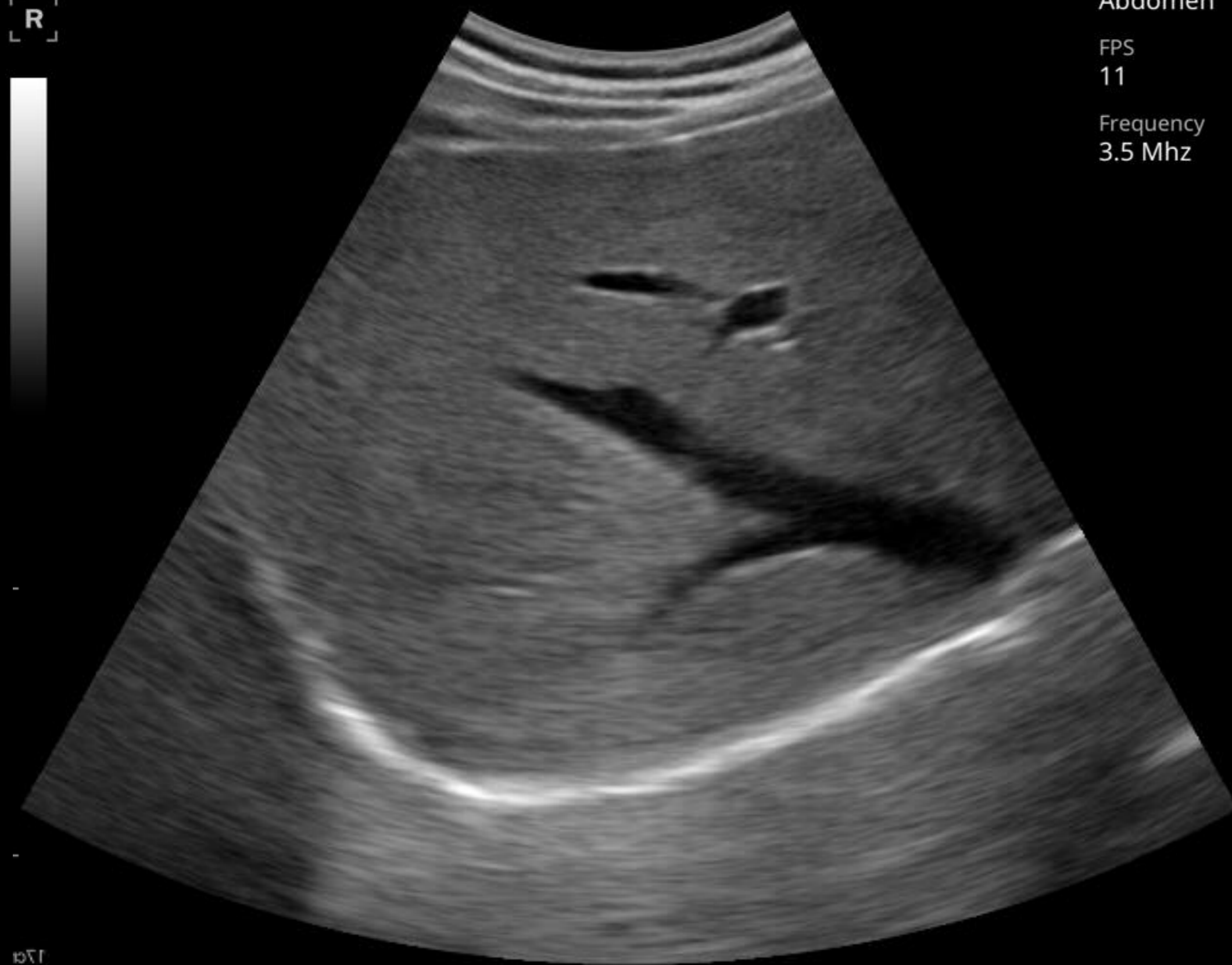Right hepatic vein portion

Abdomen : Liver

300c_new
300c_new

96%

R



17cm

Right lobe

2017/11/03 02:32:46 오후
HC | Unknown
MI:0.48 / TIB:0.20

Preset
Abdomen

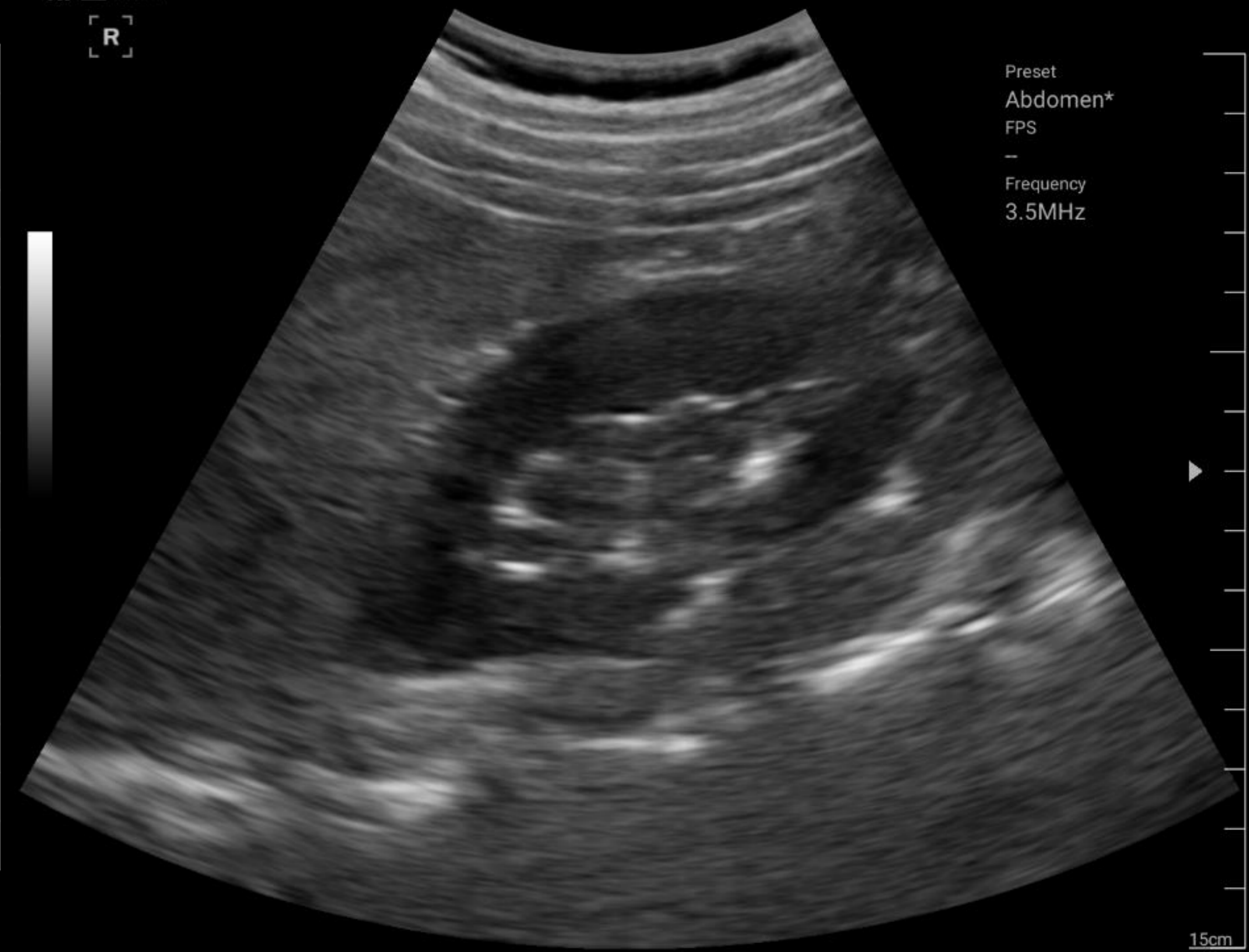FPS
11

Frequency
3.5 Mhz



100%

R



15cm

Fatty liver

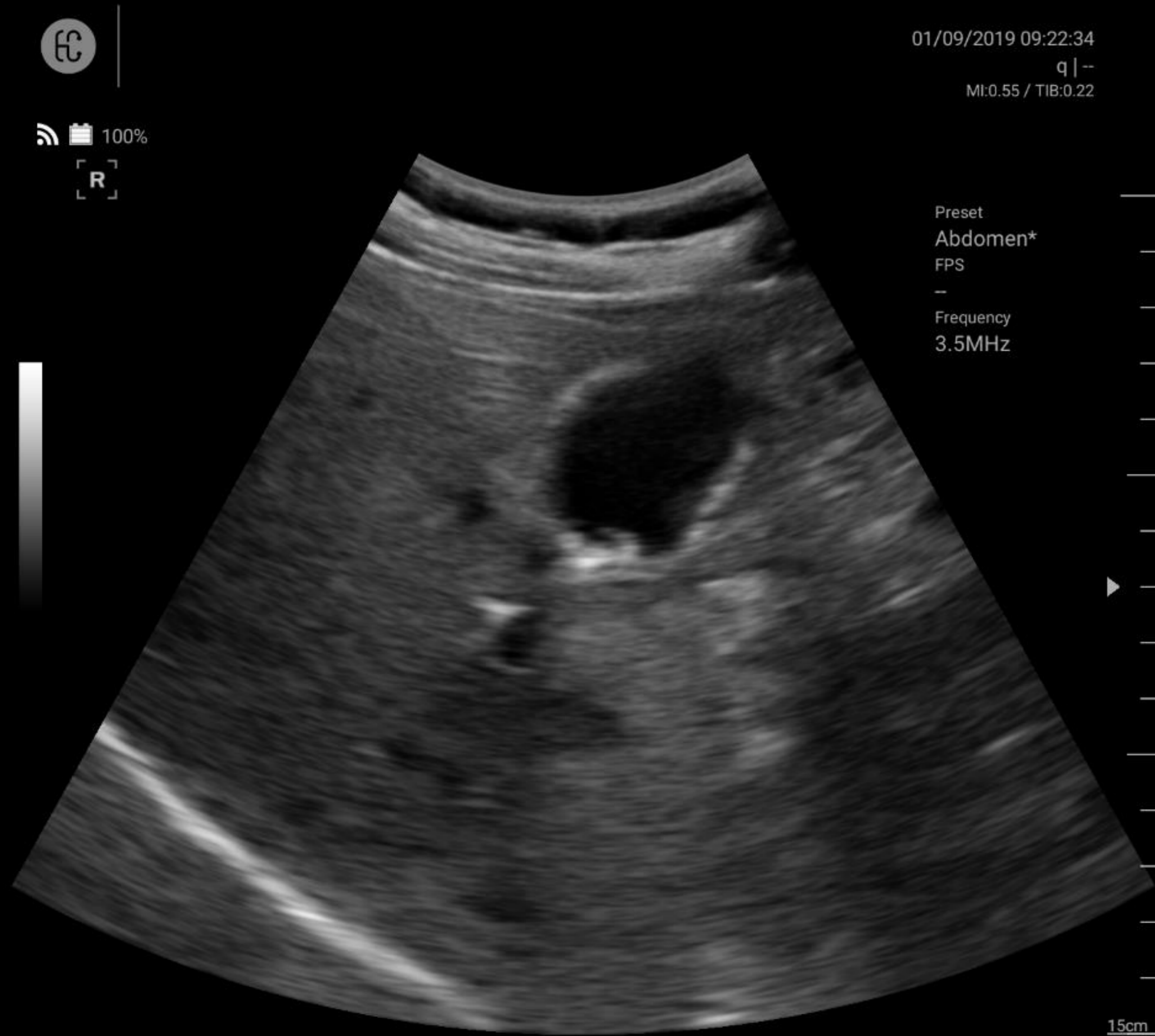01/09/2019 09:23:09
q|--
MI:0.55 / TIB:0.22

Preset
Abdomen*

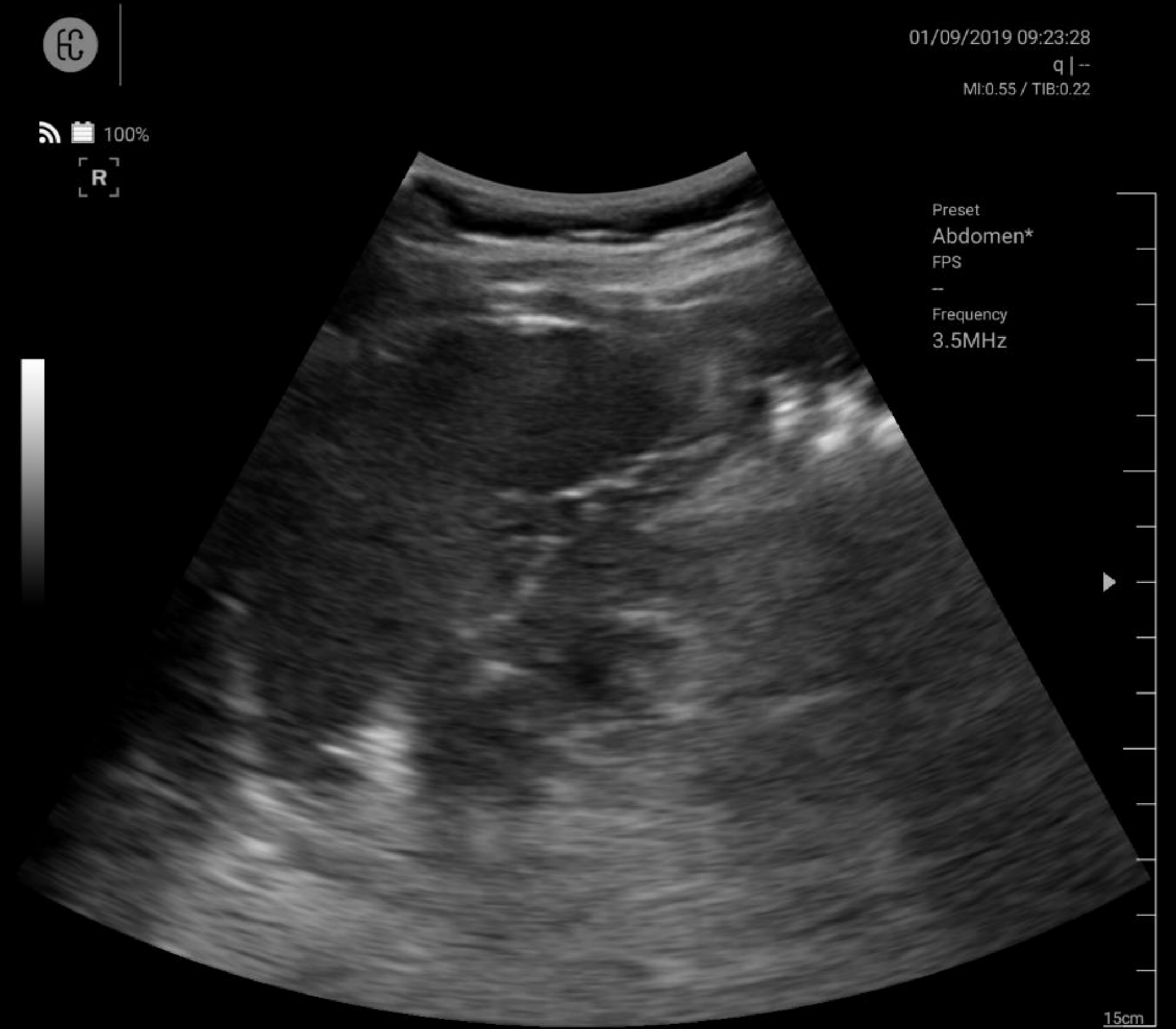
FPS
-

Frequency
3.5MHz

Abdomen : GB, Spleen



GB polyp



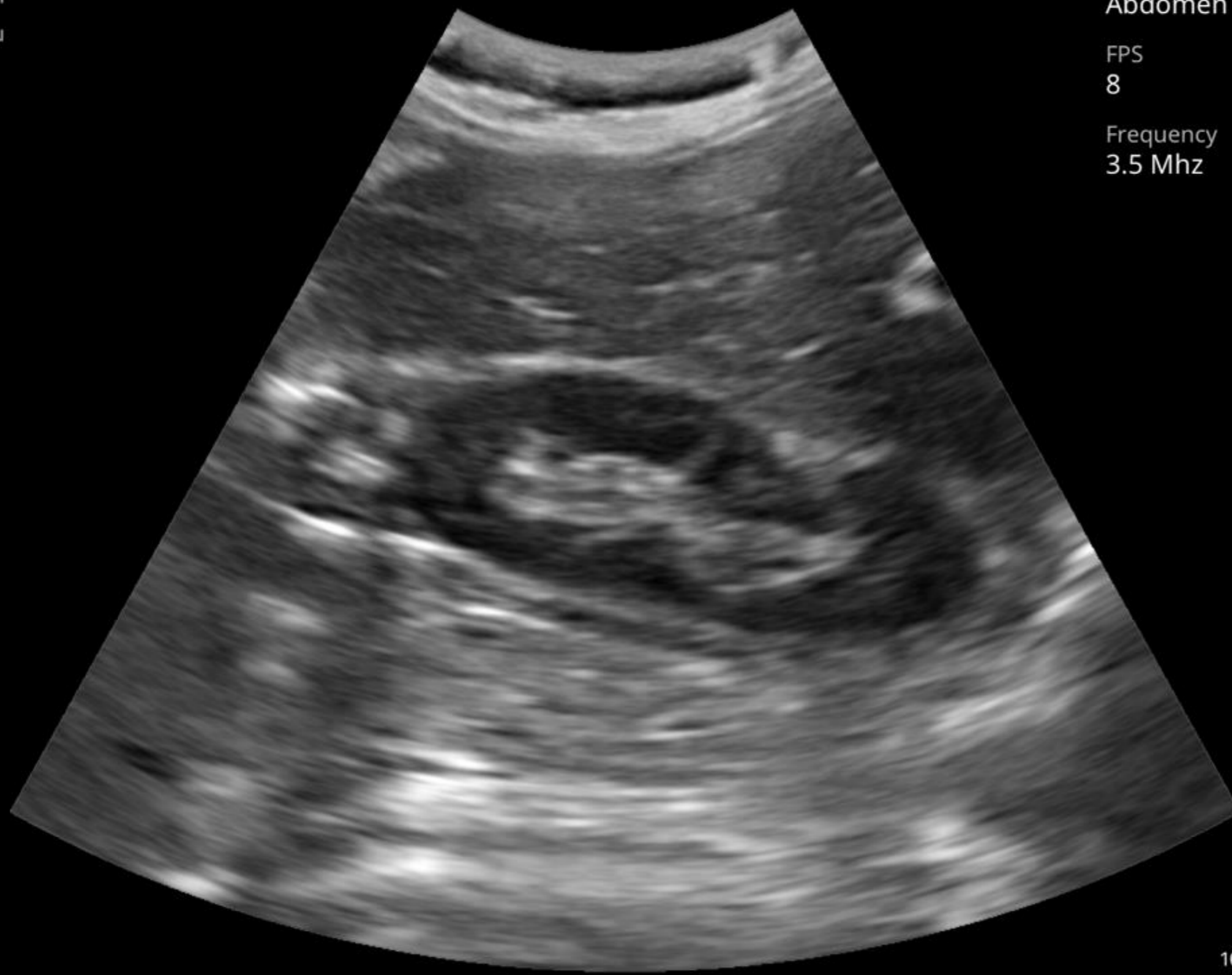
Spleen

Abdomen : Kidney/Pancreas

300c_new
300c_new

96%

R



2017/11/03 02:34:23 오후
HC | Unknown
MI:0.48 / TIB:0.20

300c_new
300c_new

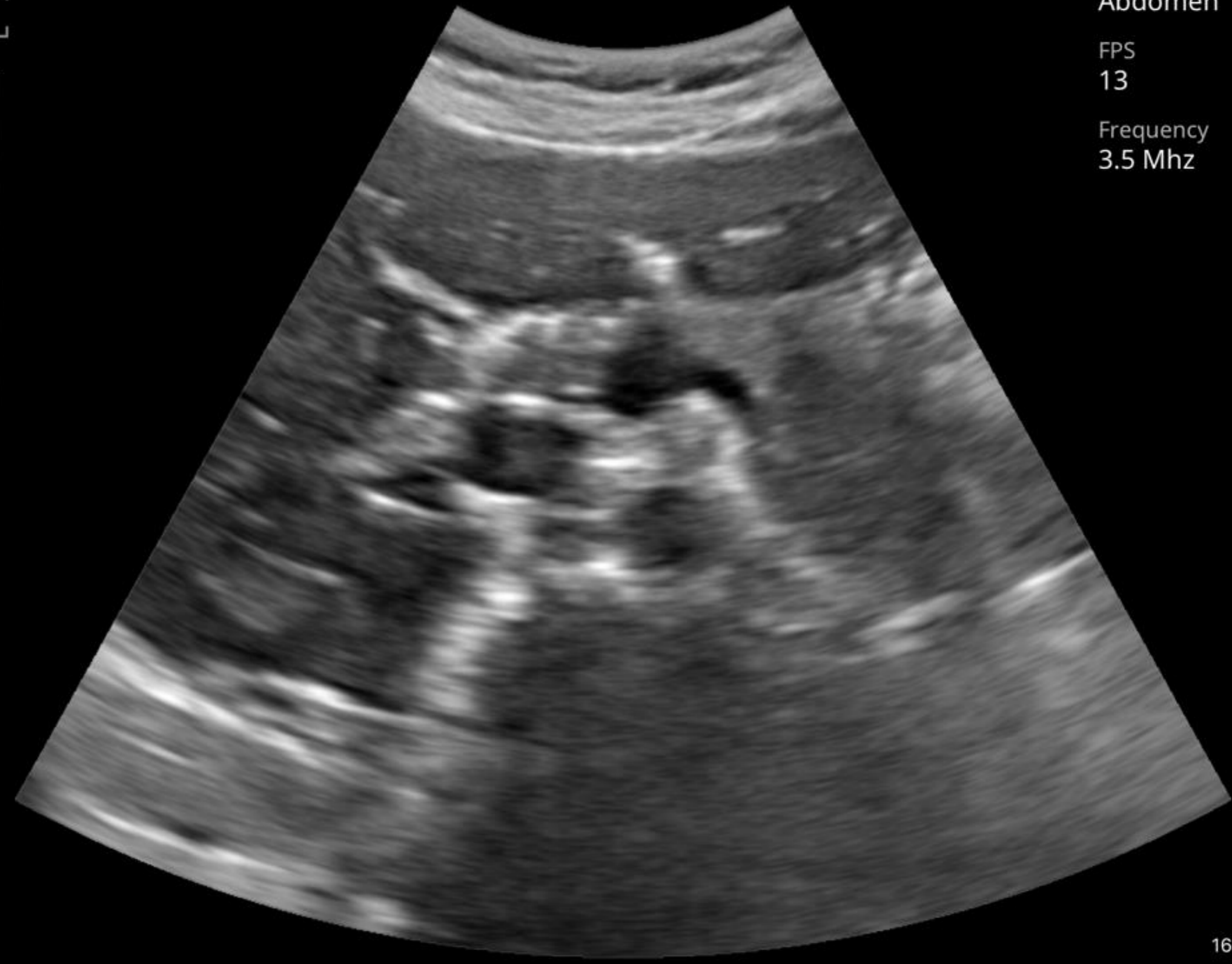
96%

Preset
Abdomen

FPS
8

Frequency
3.5 Mhz

R



2017/11/03 02:34:42 오후
HC | Unknown
MI:0.64 / TIB:0.28

Preset
Abdomen

FPS
13

Frequency
3.5 Mhz

16 cm

Thyroid

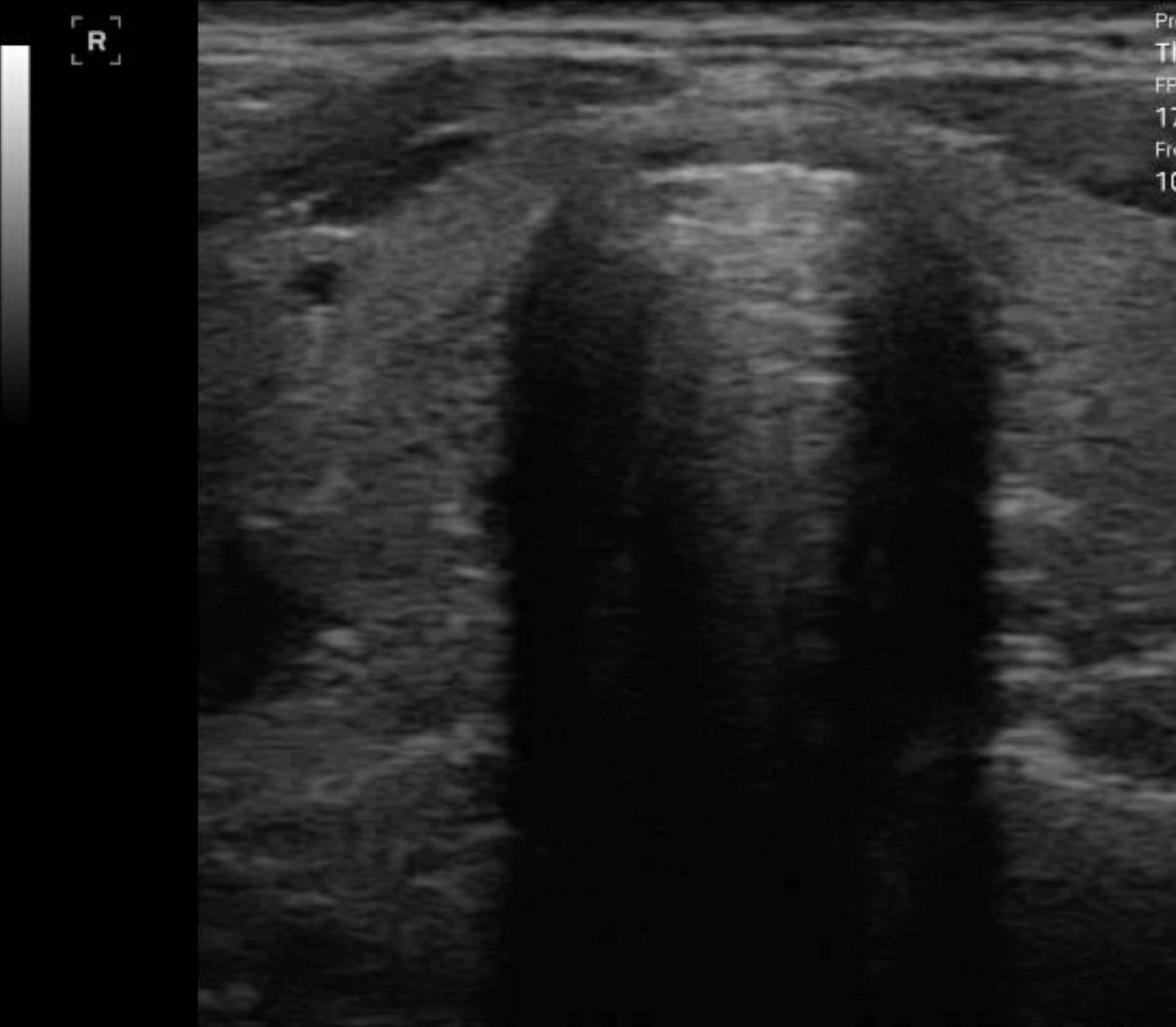
clinicalimage
1

10/19/2017 14:29:11
q | -
MI:0.73 / TIB:0.28

clinicalimage
1

10/19/2017 14:30:52
q | -
MI:0.73 / TIB:0.28

100%

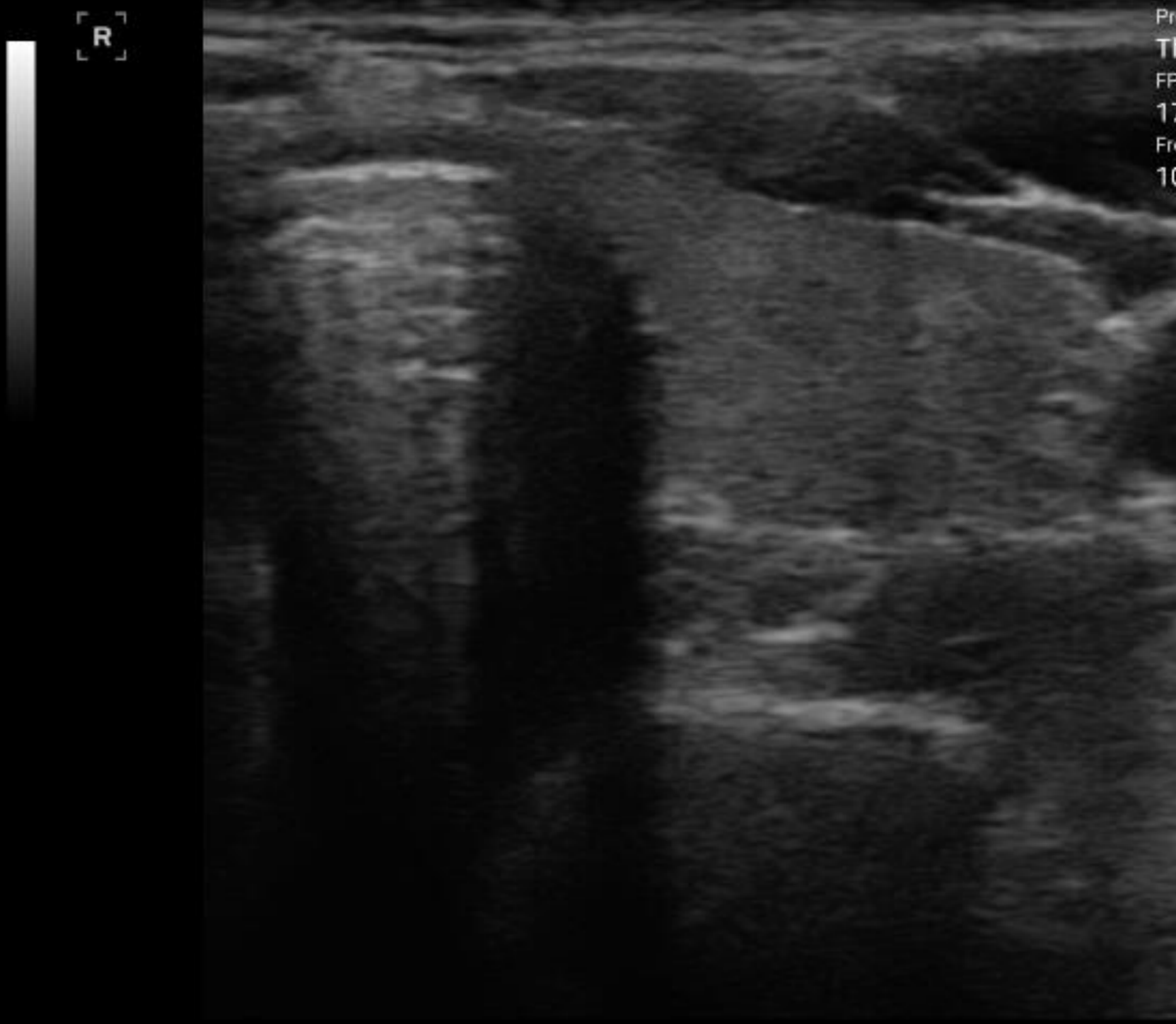


Preset
Thyroid
FPS
17
Frequency
10MHz

4cm



100%



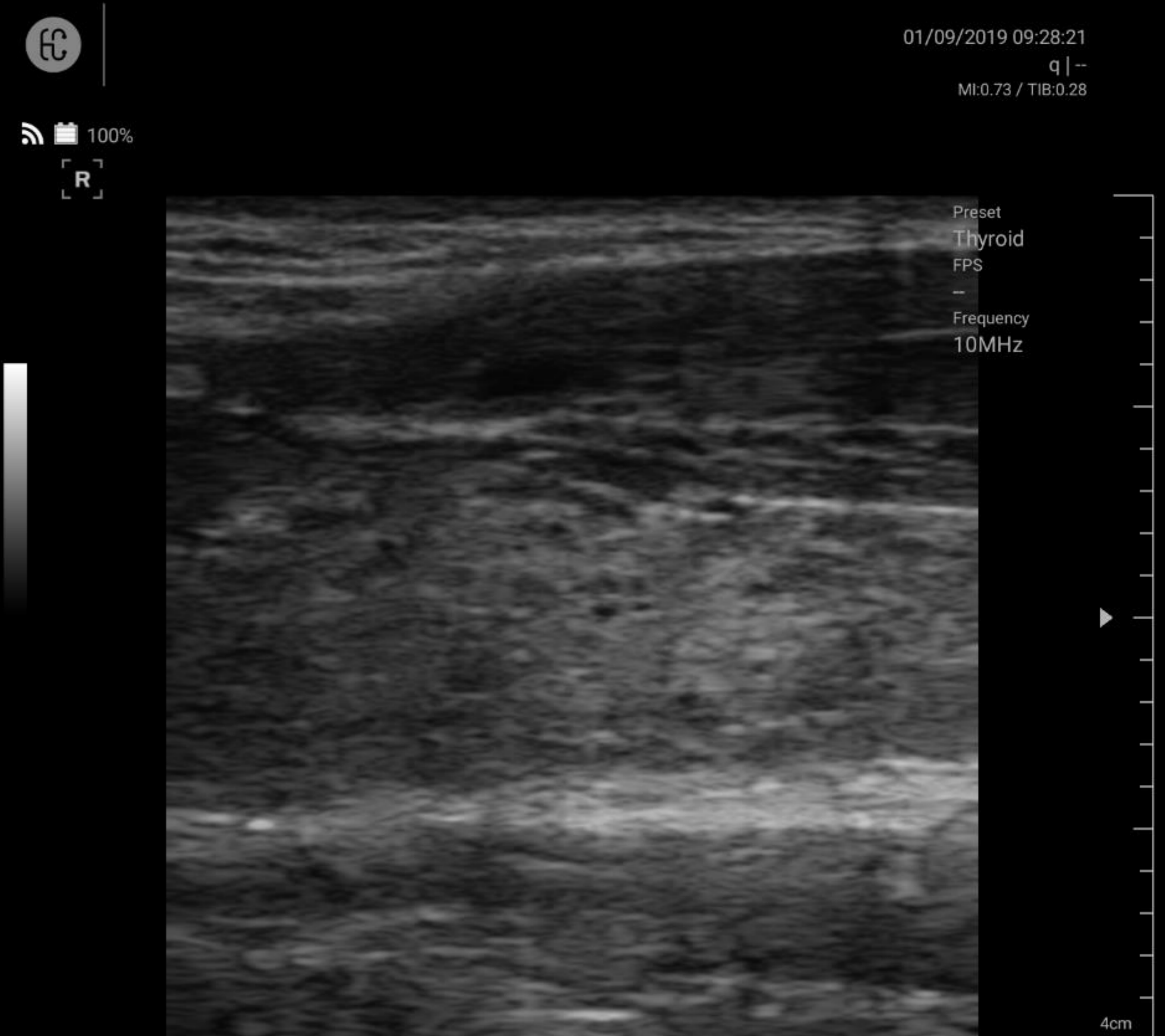
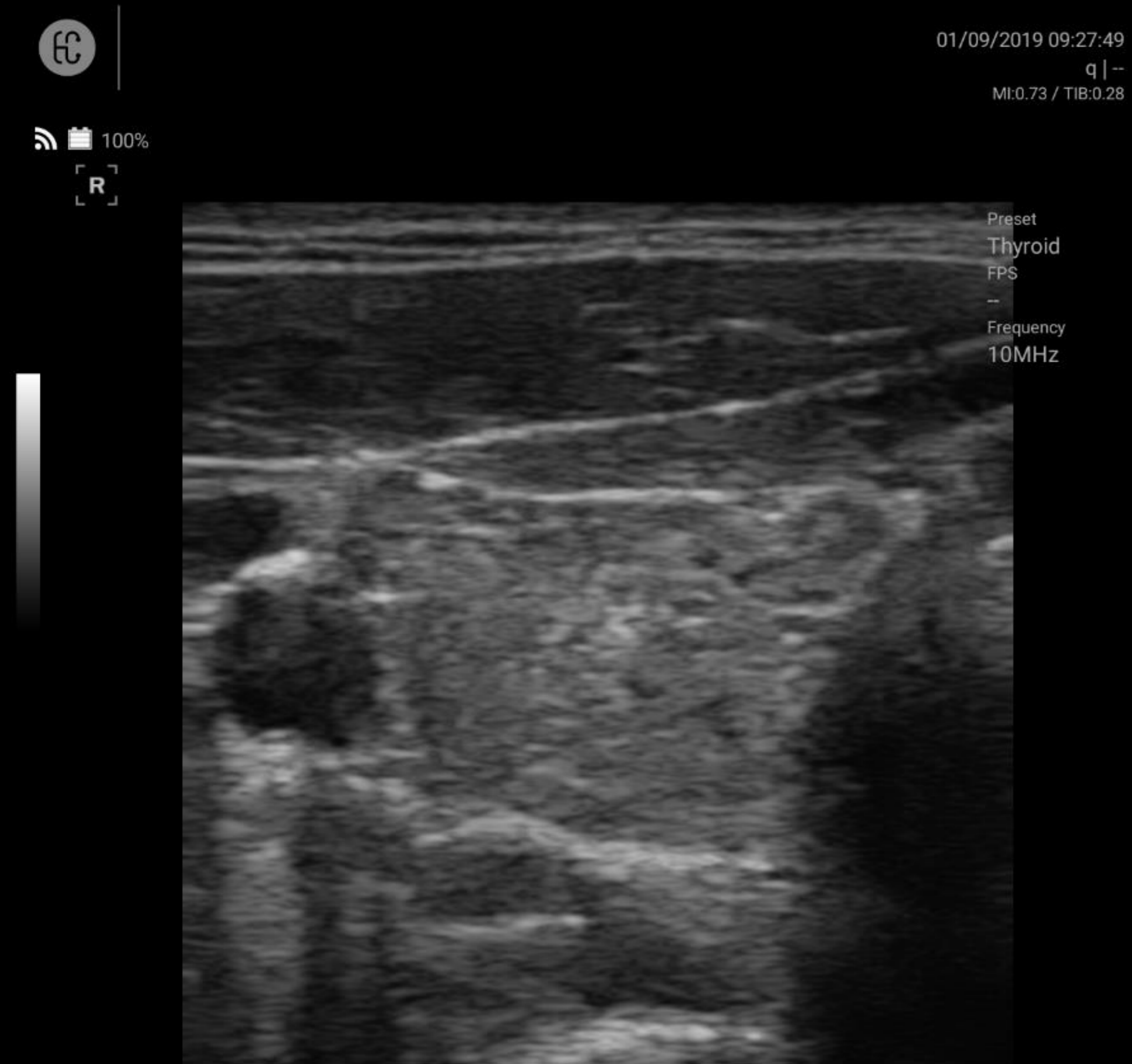
Preset
Thyroid
FPS
17
Frequency
10MHz

4cm



Normal thyroid lobes

Thyroid



Hyperthyroidism

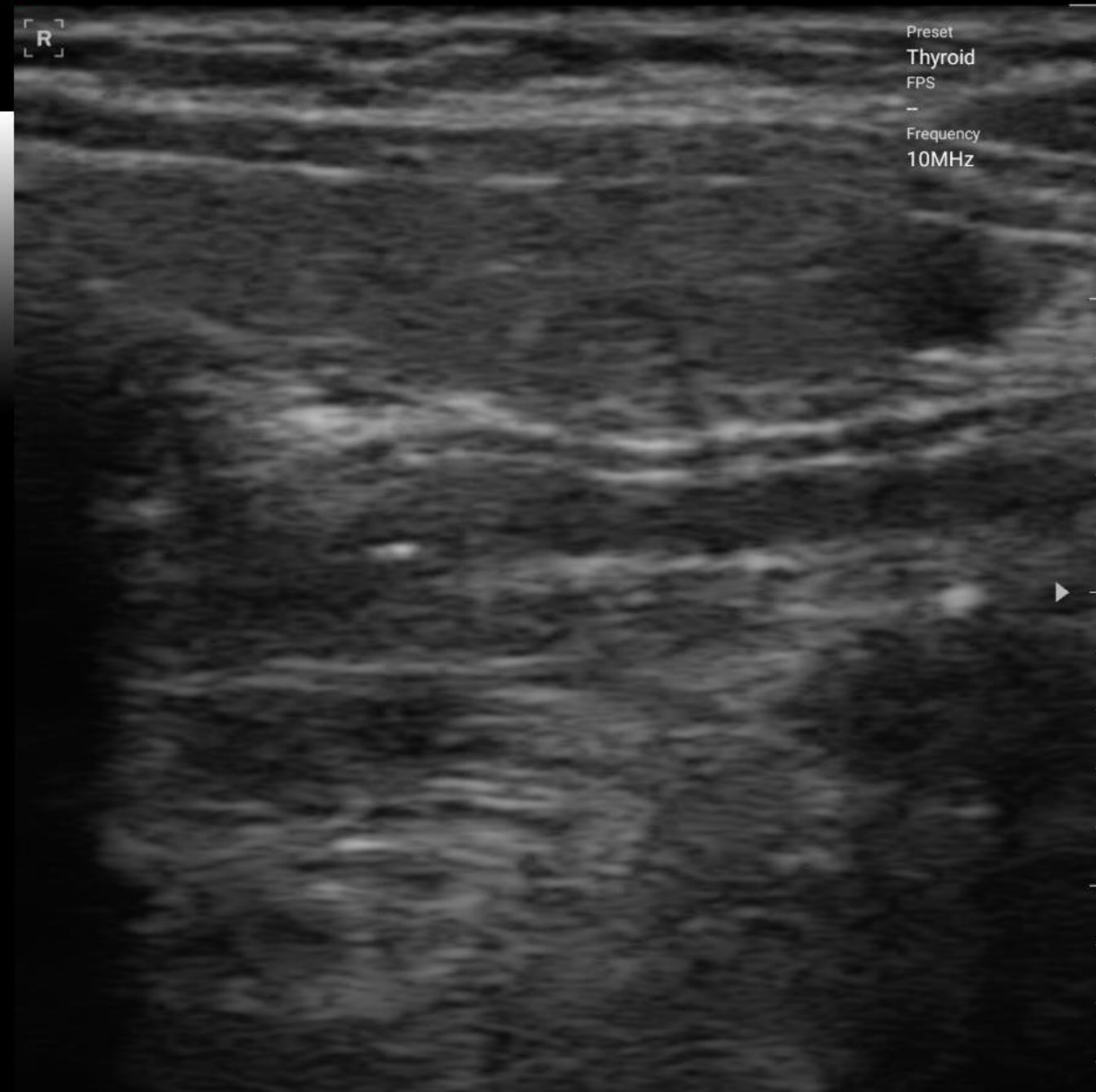
Thyroid



yoo yoo
180226

02/23/2018 12:15:07
q | -
MI:0.73 / TIB:0.28

94%



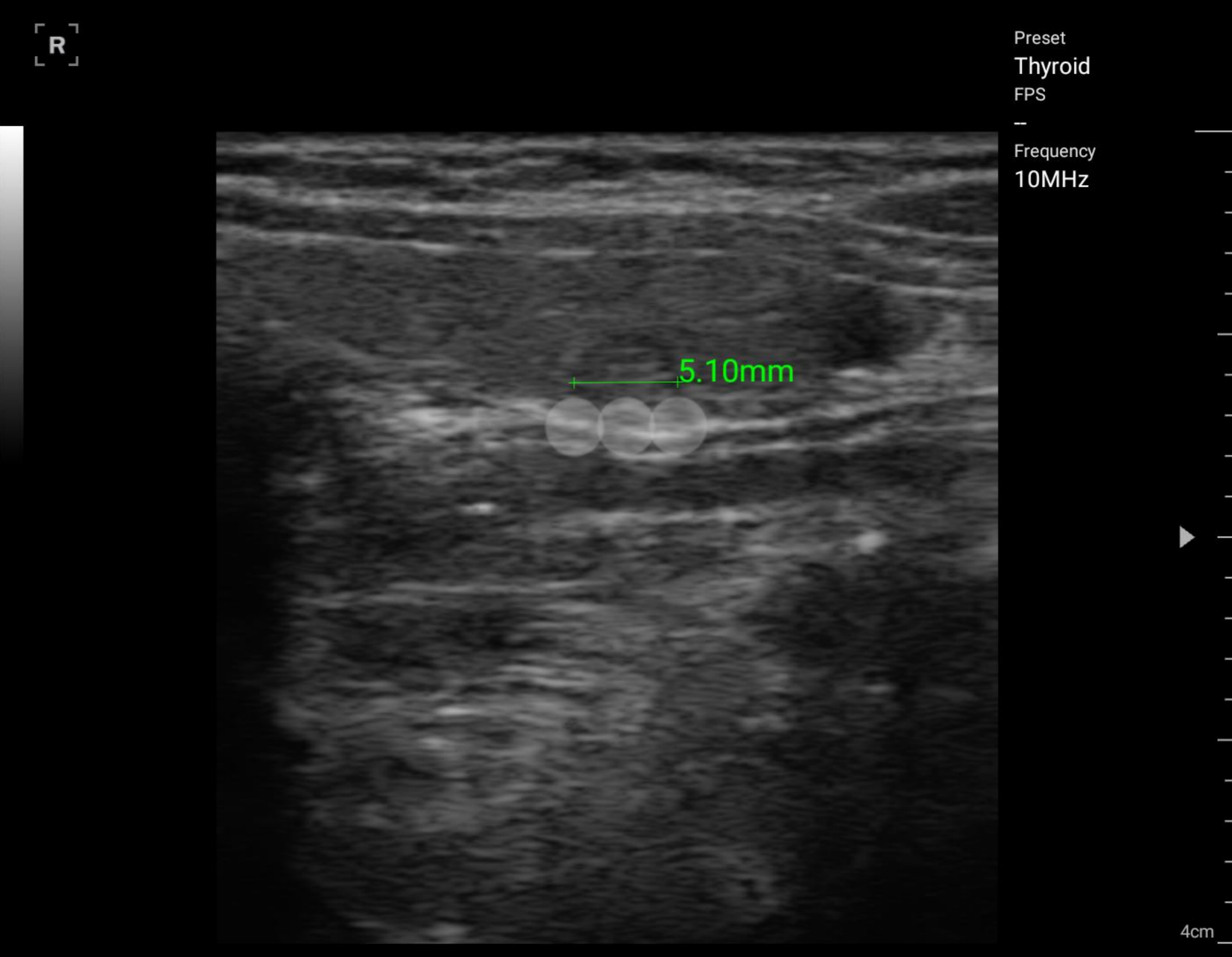
Preset
Thyroid
FPS
-
Frequency
10MHz



yoo yoo
180226

02/23/2018 12:15:59
q | -
MI:0.73 / TIB:0.28

94%



5.10mm

Preset
Thyroid
FPS
-
Frequency
10MHz

4cm



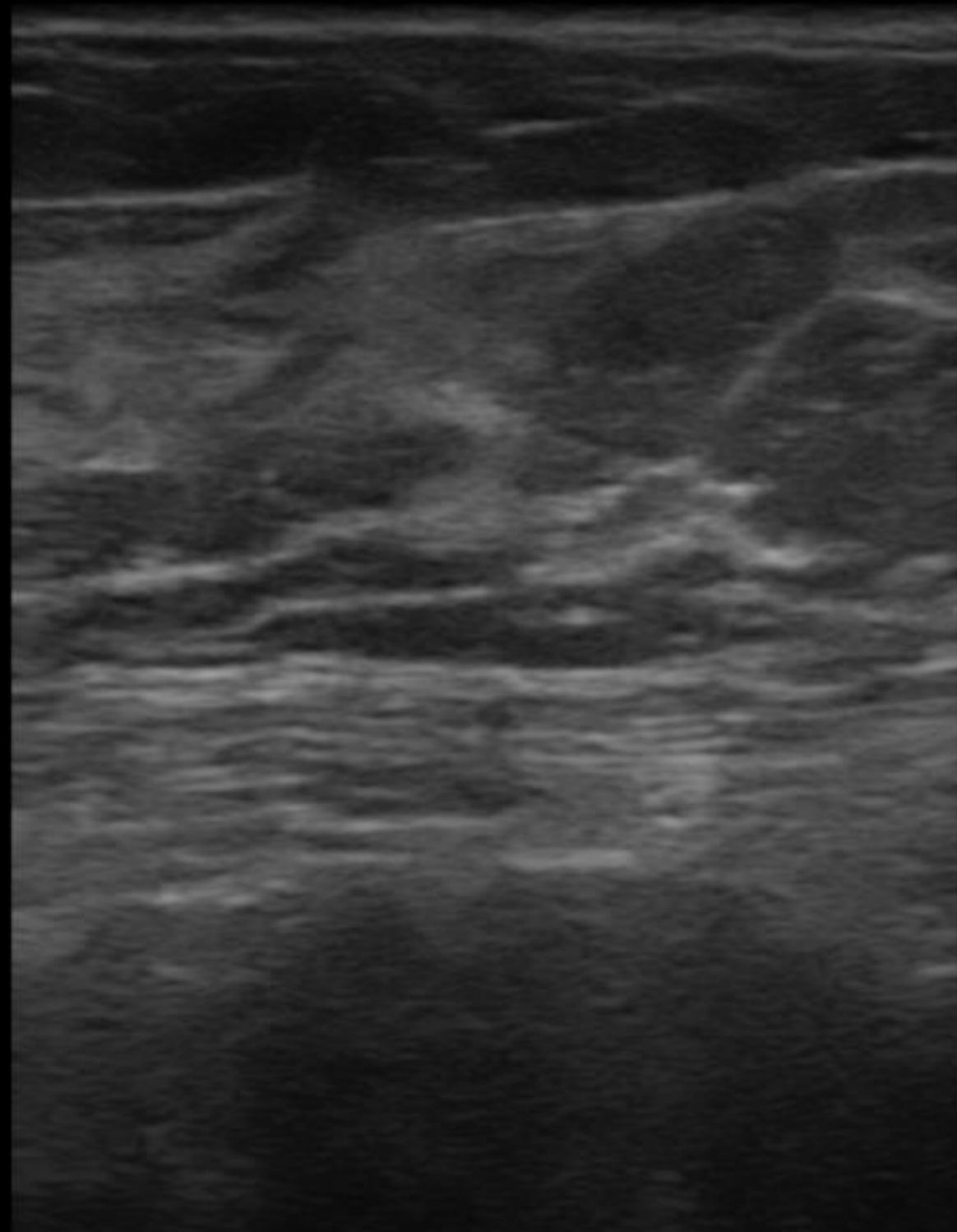
Thyroid benign nodule

Breast



20170108

[R]



01/09/2017 12:49:32 오전
Healcerion | Erika
MI:0.82 / TIB:0.33



20170108

Preset
Breast

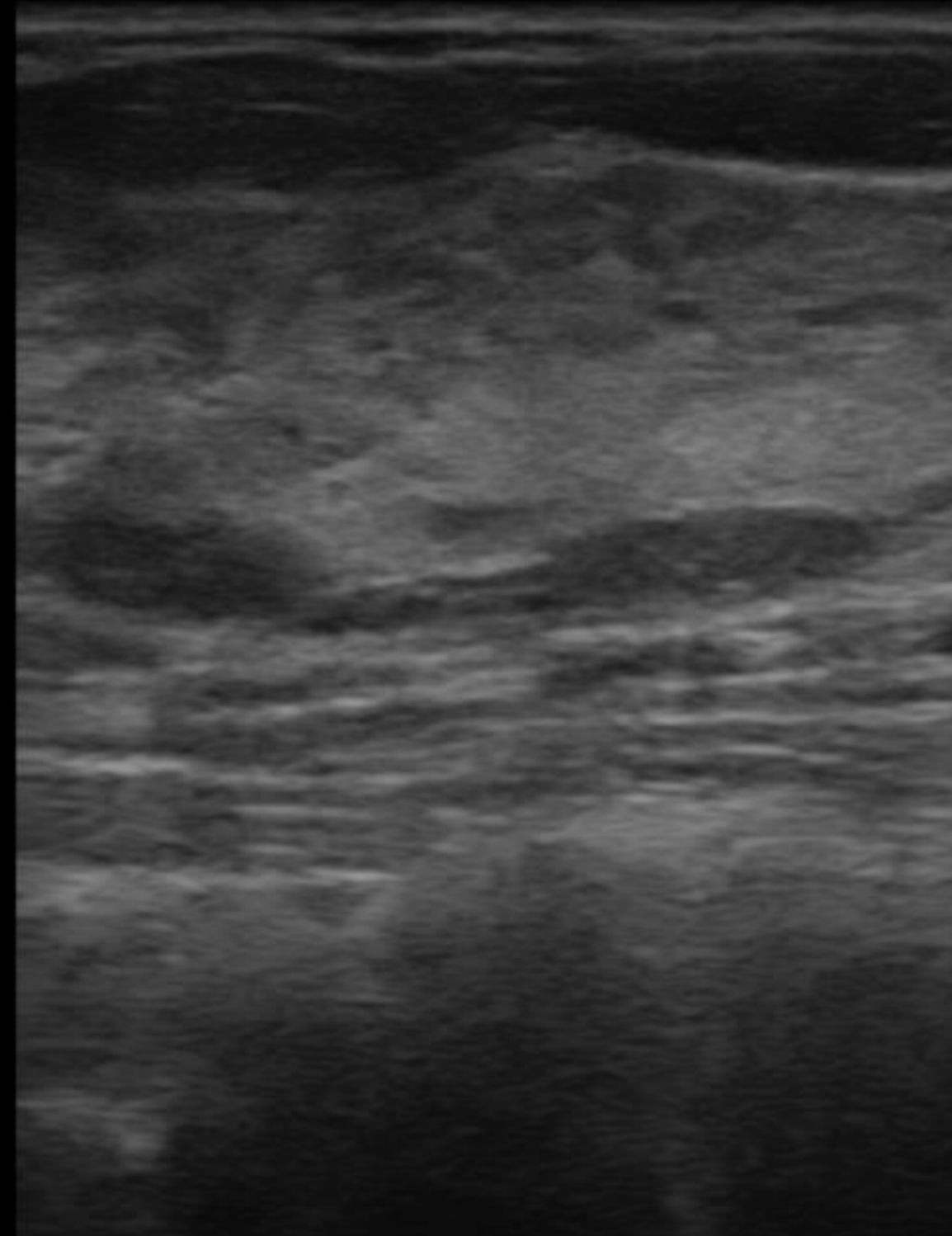
FPS
0

Frequency
10 Mhz

[R]



5 cm




01/09/2017 12:50:08 오전
Healcerion | Erika
MI:0.82 / TIB:0.33

Preset
Breast

FPS
0

Frequency
10 Mhz

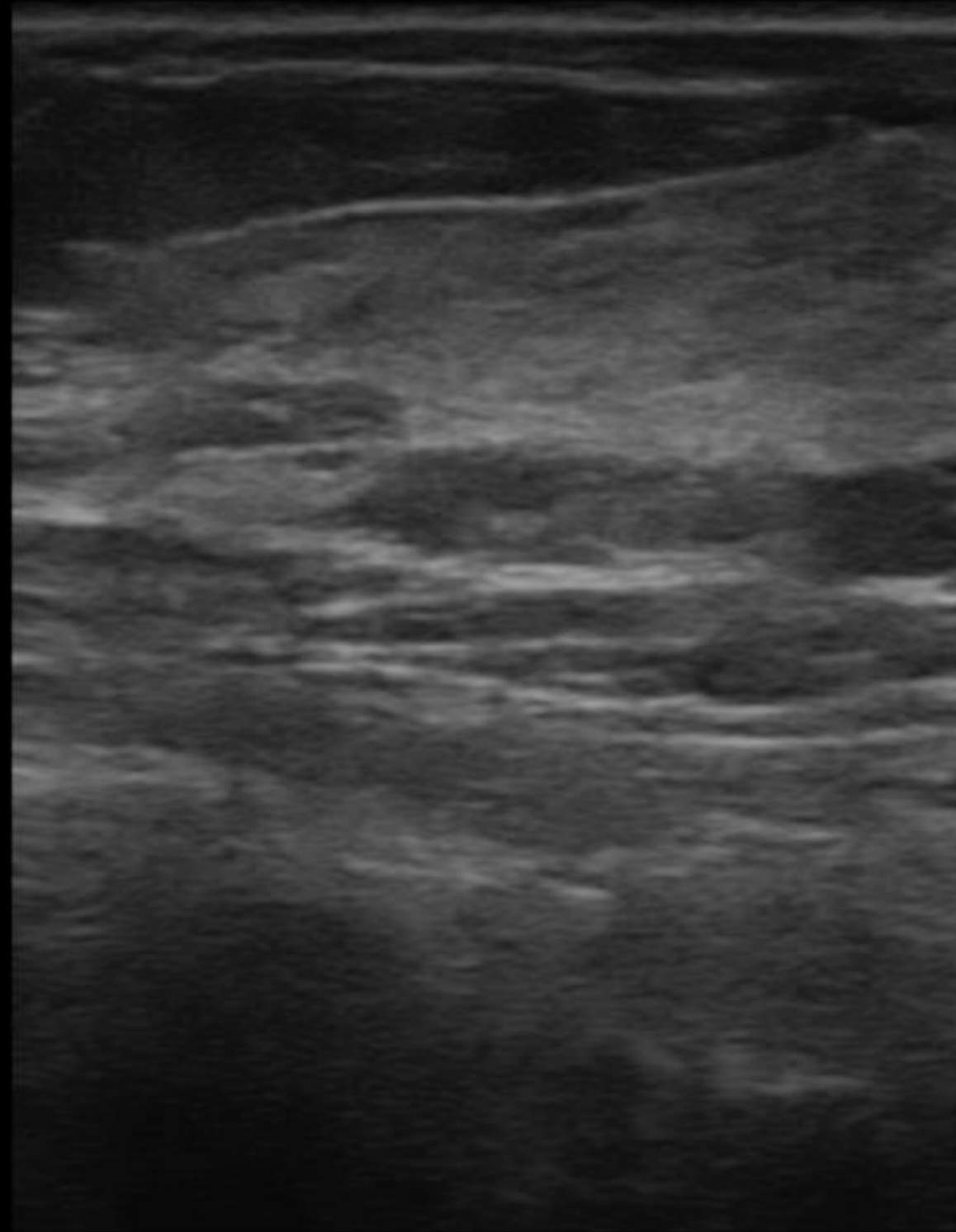



5 cm

Breast



[R]



01/09/2017 12:49:42 오전
Healcerion | Erika
MI:0.82 / TIB:0.33



20170108

Preset
Breast

FPS
0

Frequency
10 Mhz

[R]



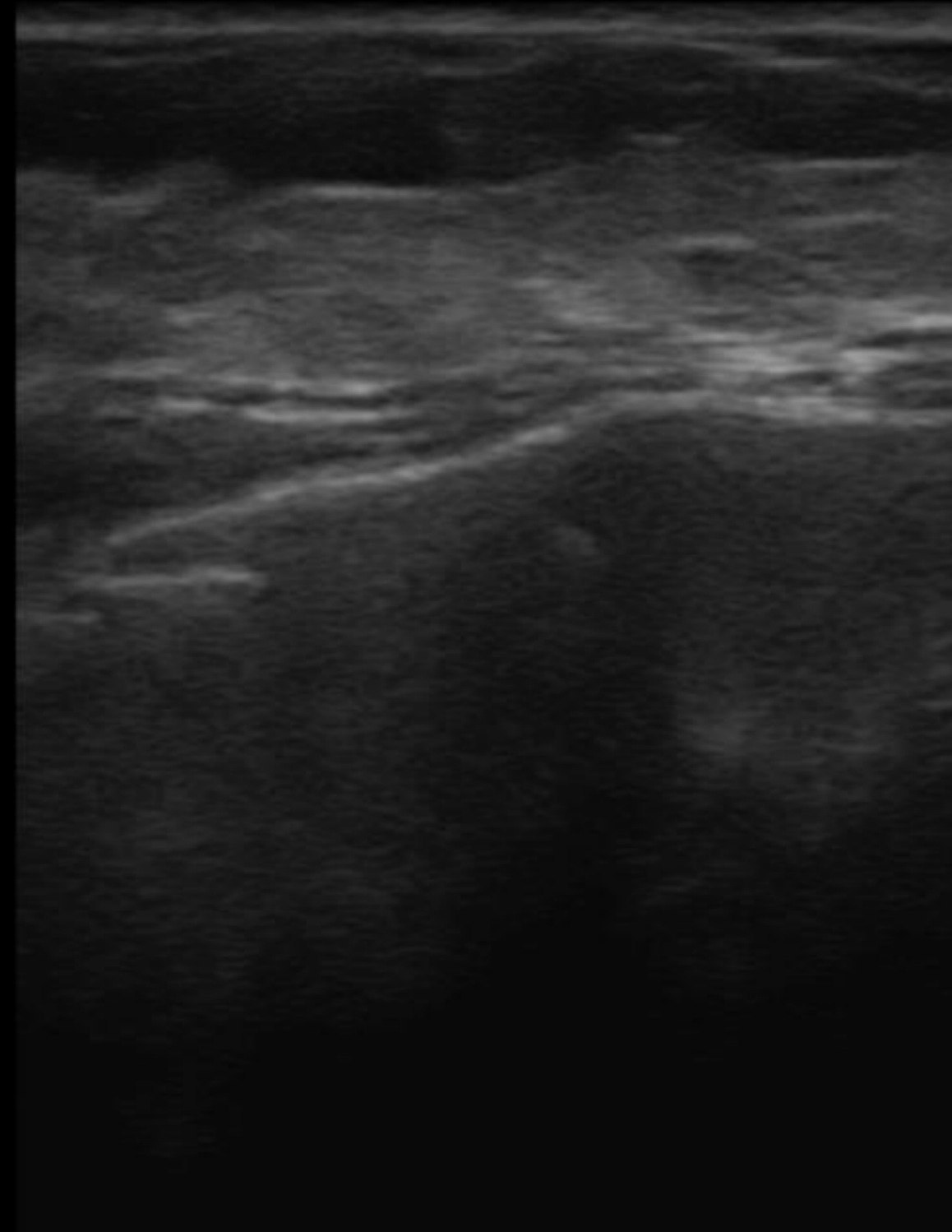
5 cm

01/09/2017 12:49:13 오전
Healcerion | Erika
MI:0.82 / TIB:0.33

Preset
Breast

FPS
0

Frequency
10 Mhz



5 cm

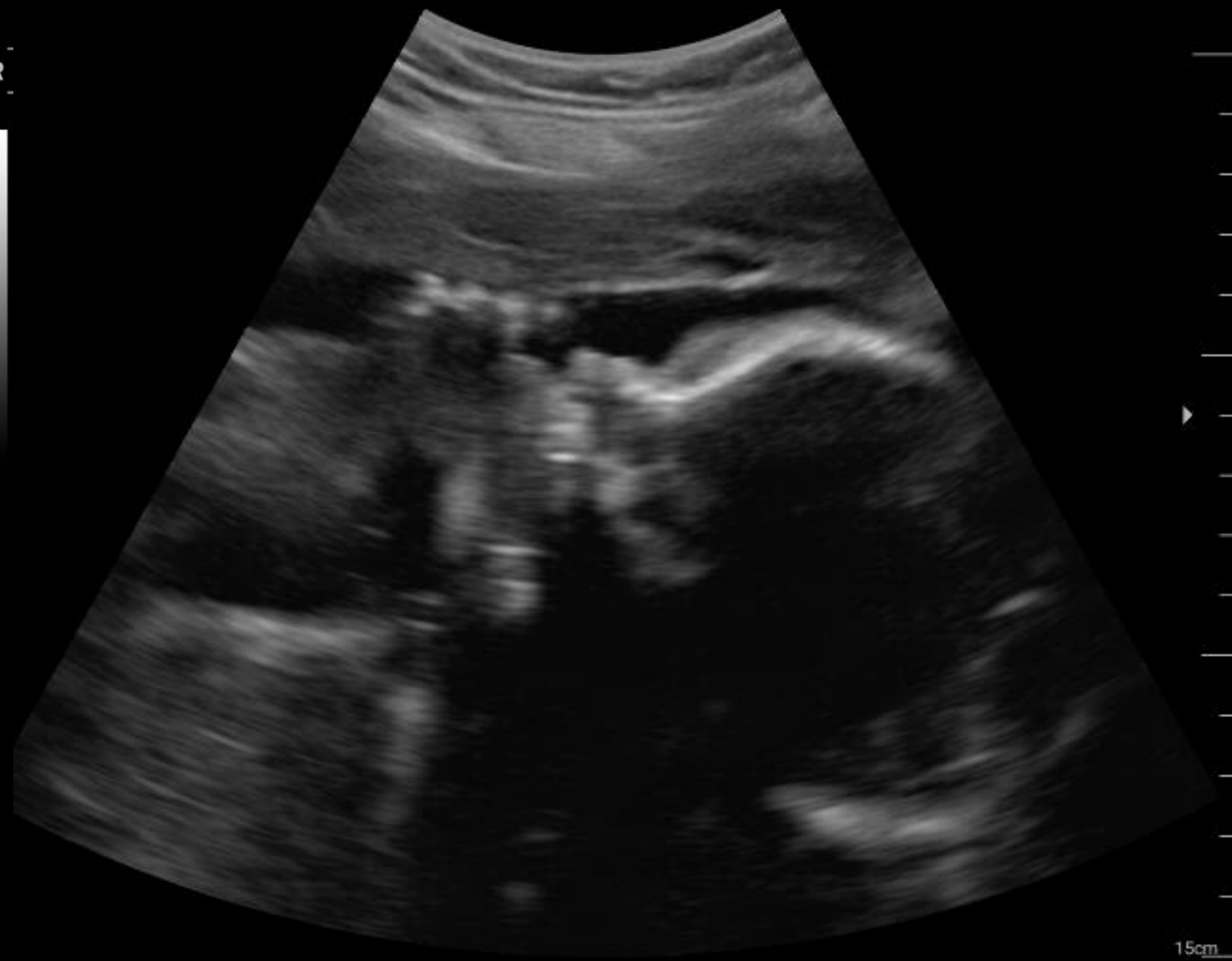OB Gyn

Obstetric

300c_new
300c_new

96%

R



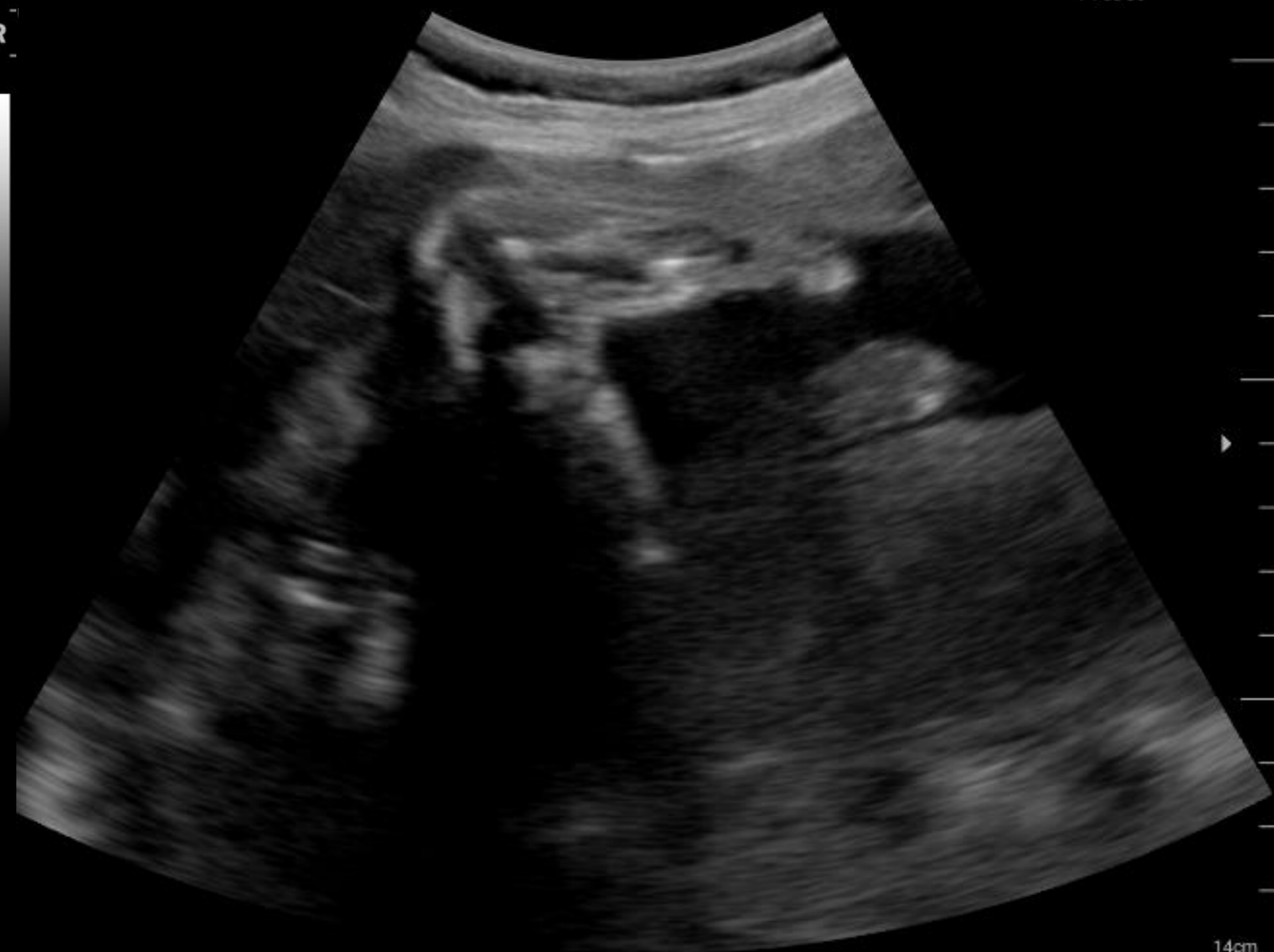Face

2017/11/03 02:34:23 오후
HC | Unknown
MI:0.48 / TIB:0.20

300c_new
300c_new

96%

R



Foot

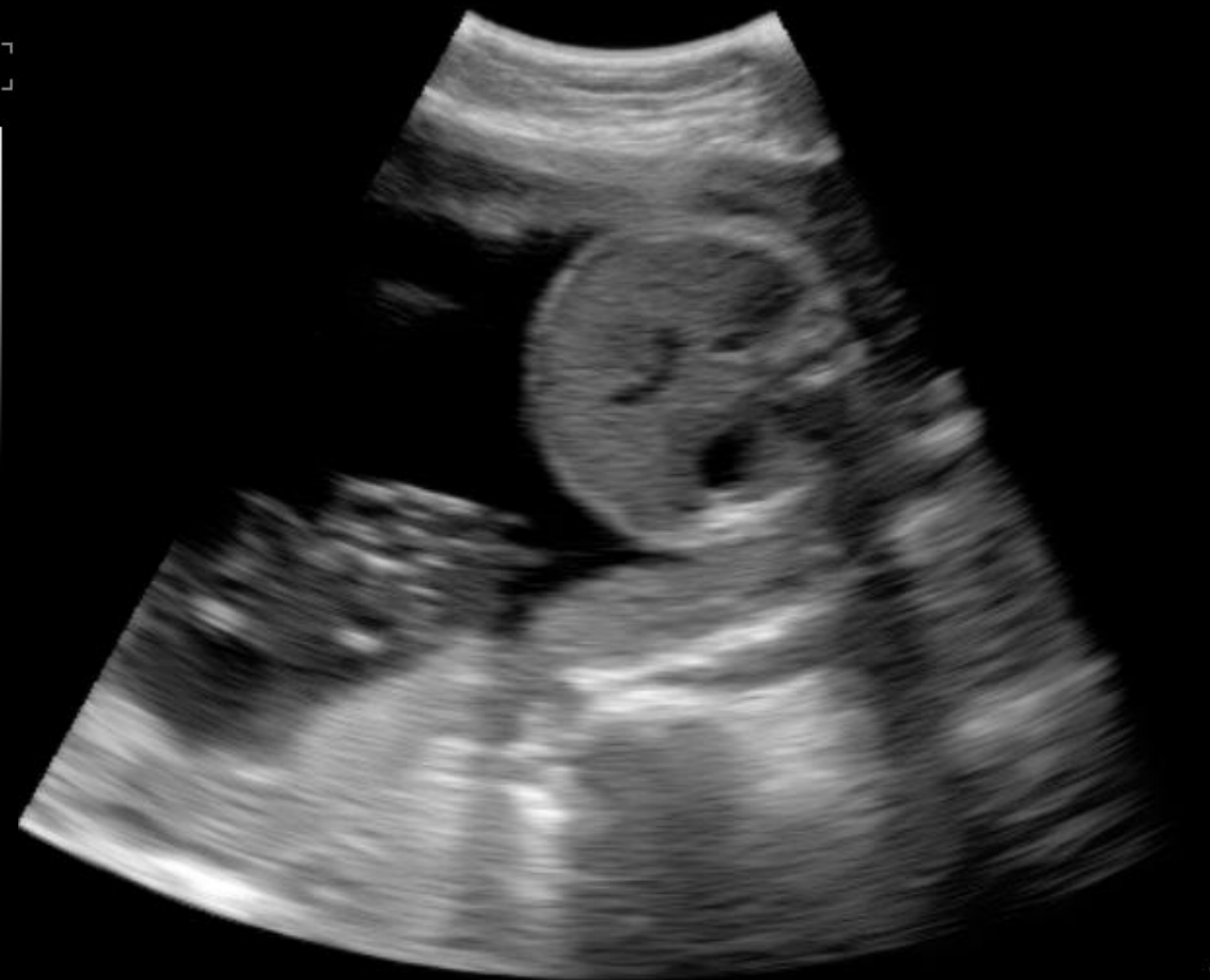2017/11/03 02:34:23 오후
HC | Unknown
MI:0.48 / TIB:0.20

Obstetric

300c_new
300c_new

96%

R



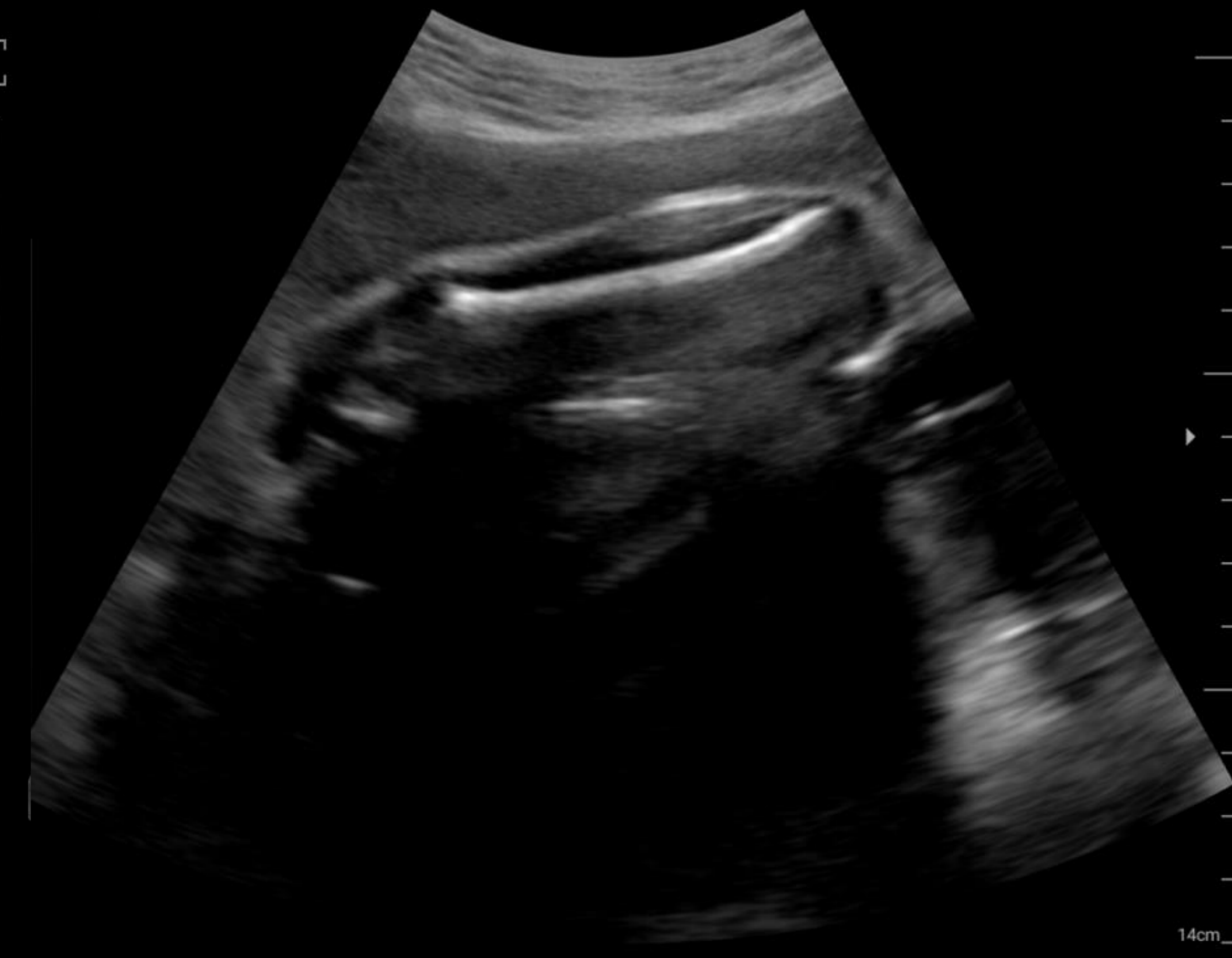Abdomen

2017/11/03 02:34:23 오후
HC | Unknown
MI:0.48 / TIB:0.20

300c_new
300c_new

96%

R



Femur

2017/11/03 02:34:23 오후
HC | Unknown
MI:0.48 / TIB:0.20

14cm

Superficial

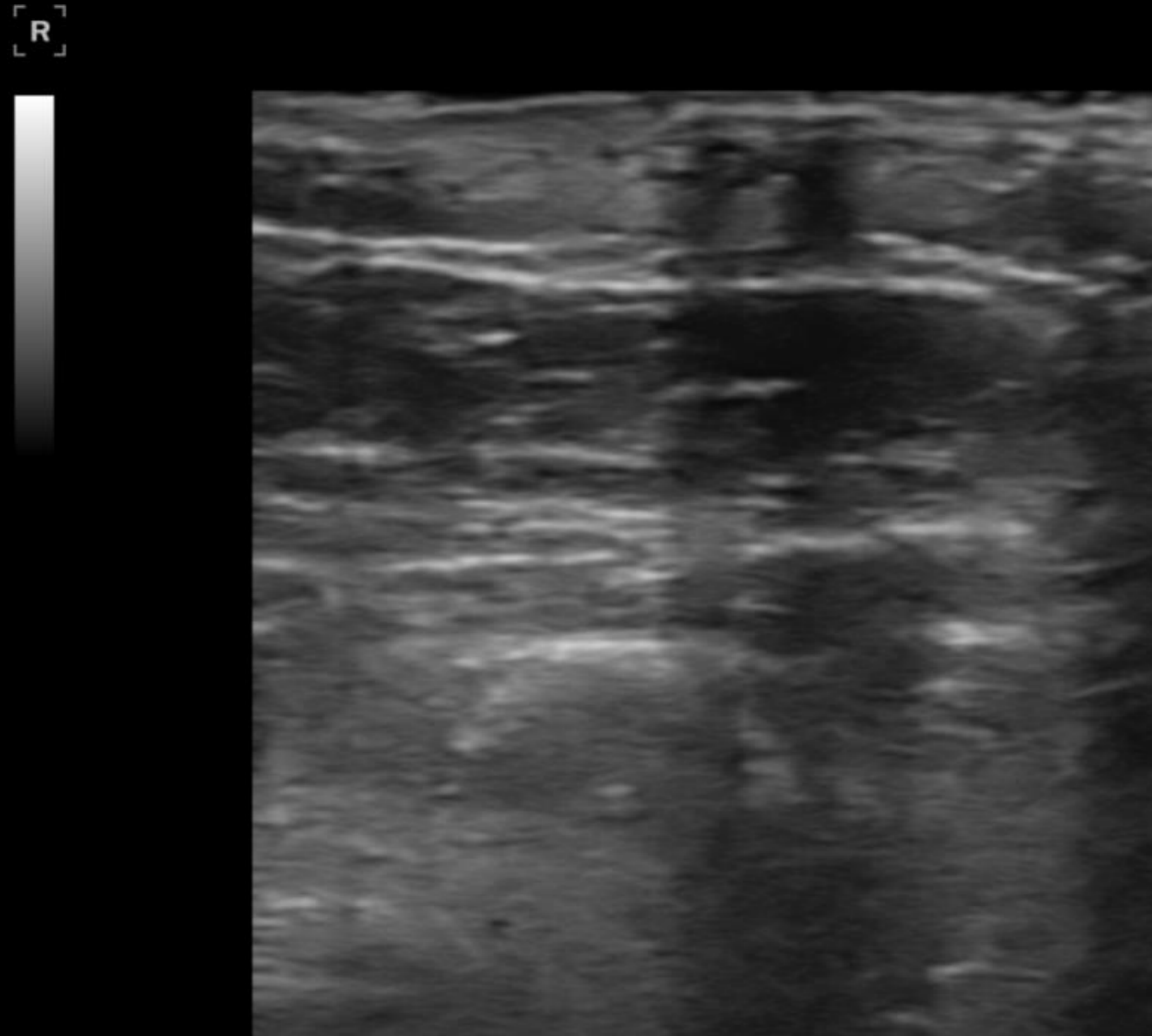
Dermatology

20170208-1
20170208-1

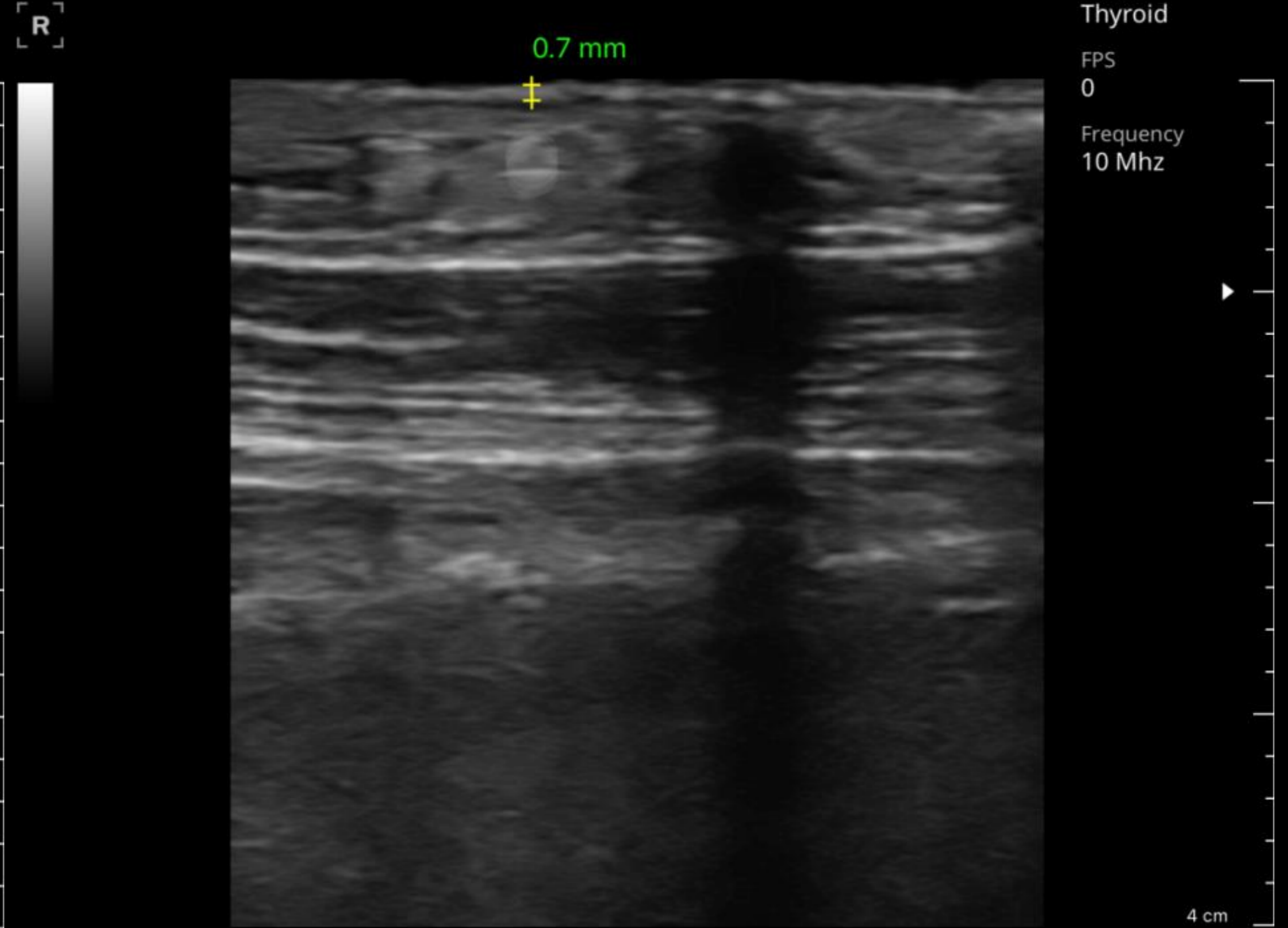
02/08/2017 09:01:40 오전
Healcerion | Unknown
MI:0.00 / TIB:0.00

20170208-1
20170208-1

02/08/2017 09:17:49 오전
Healcerion | Unknown
MI:0.00 / TIB:0.00



Congenital melanocytic nevus

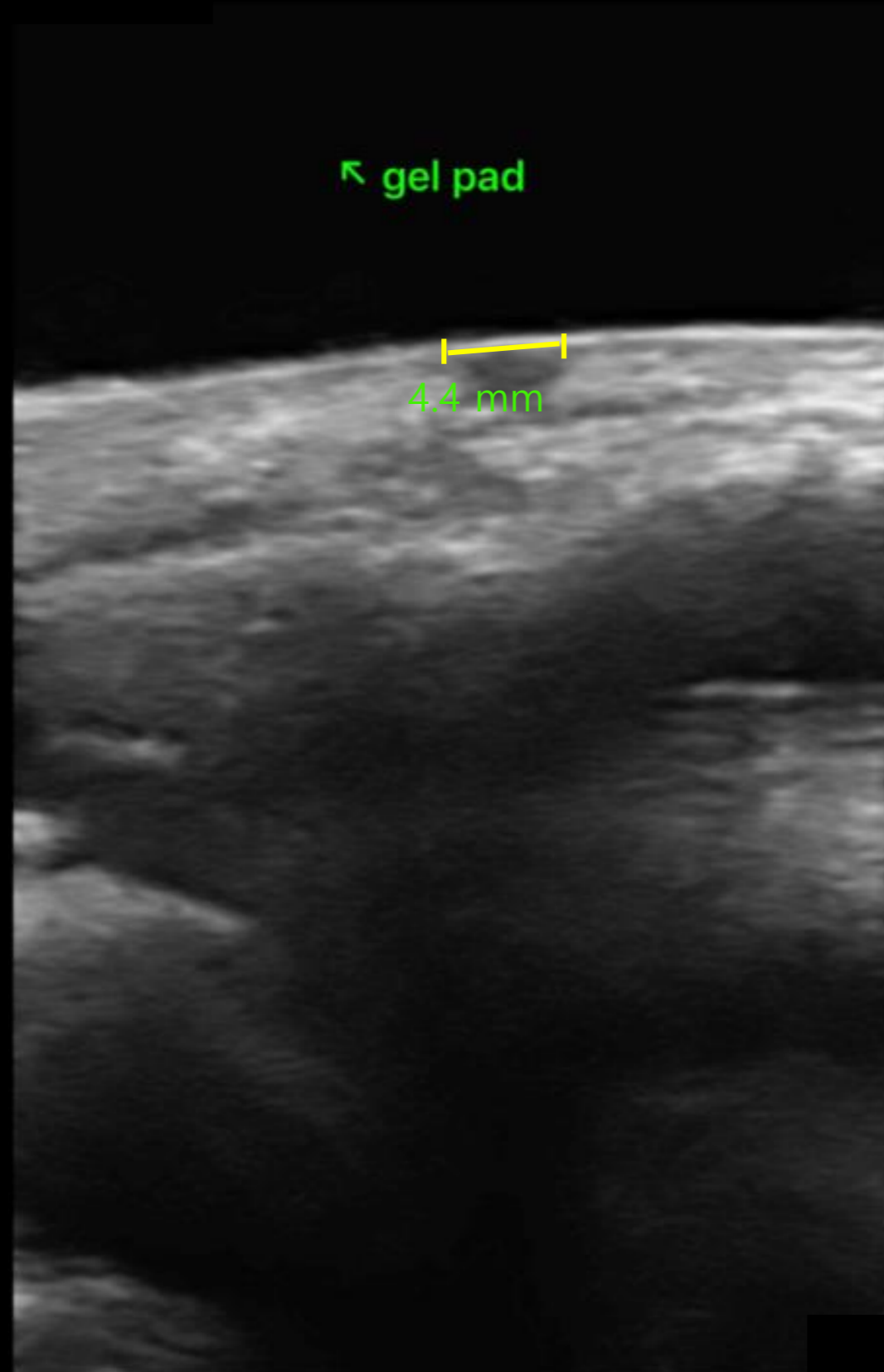


Congenital melanocytic nevus

Dermatology



R



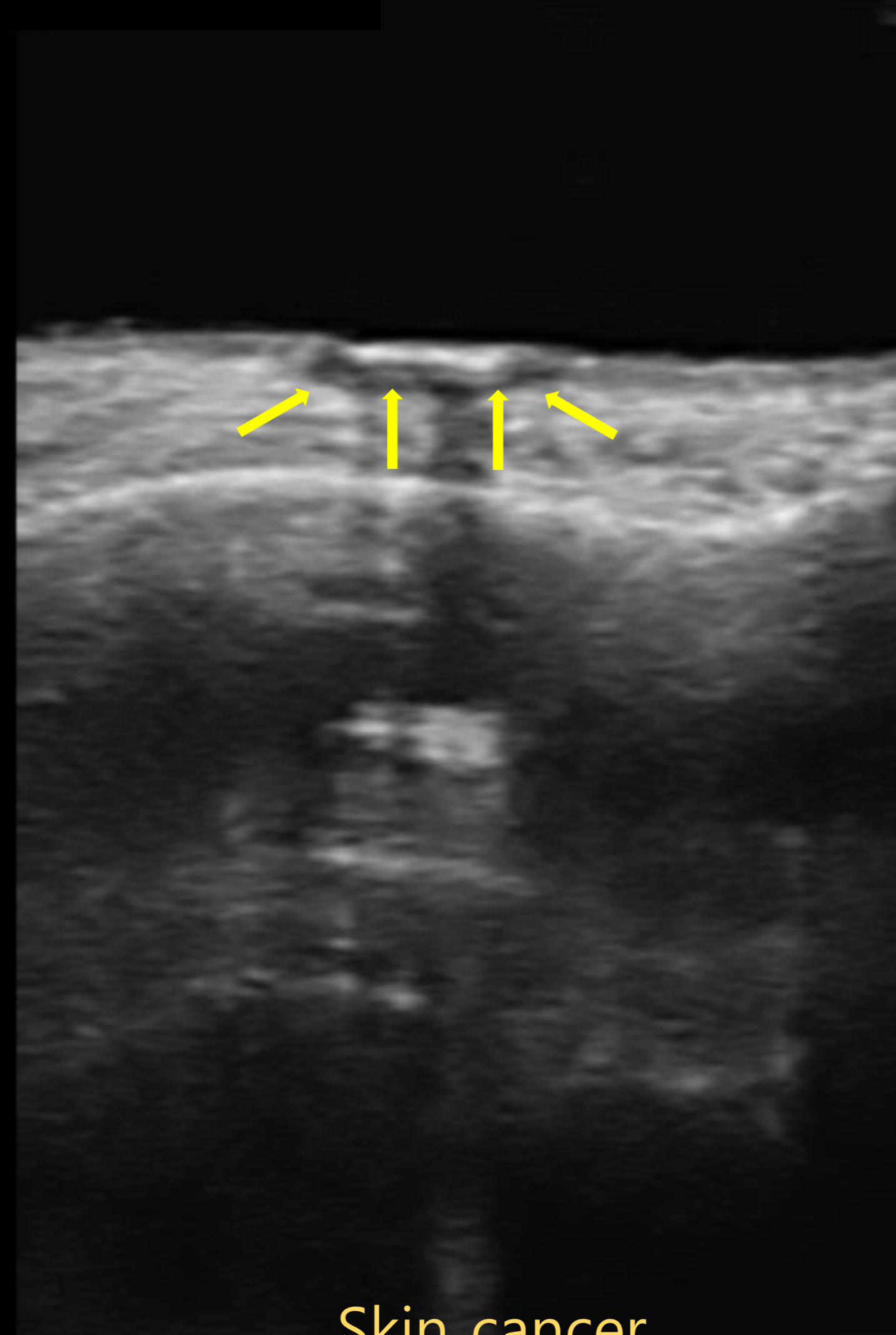
Epidermal cyst

02/08/2017 10:12:19 오전
Healcerion | Unknown
MI:0.82 / TIB:0.33



Preset
Thyroid
FPS
0
Frequency
10 Mhz

R




Skin cancer

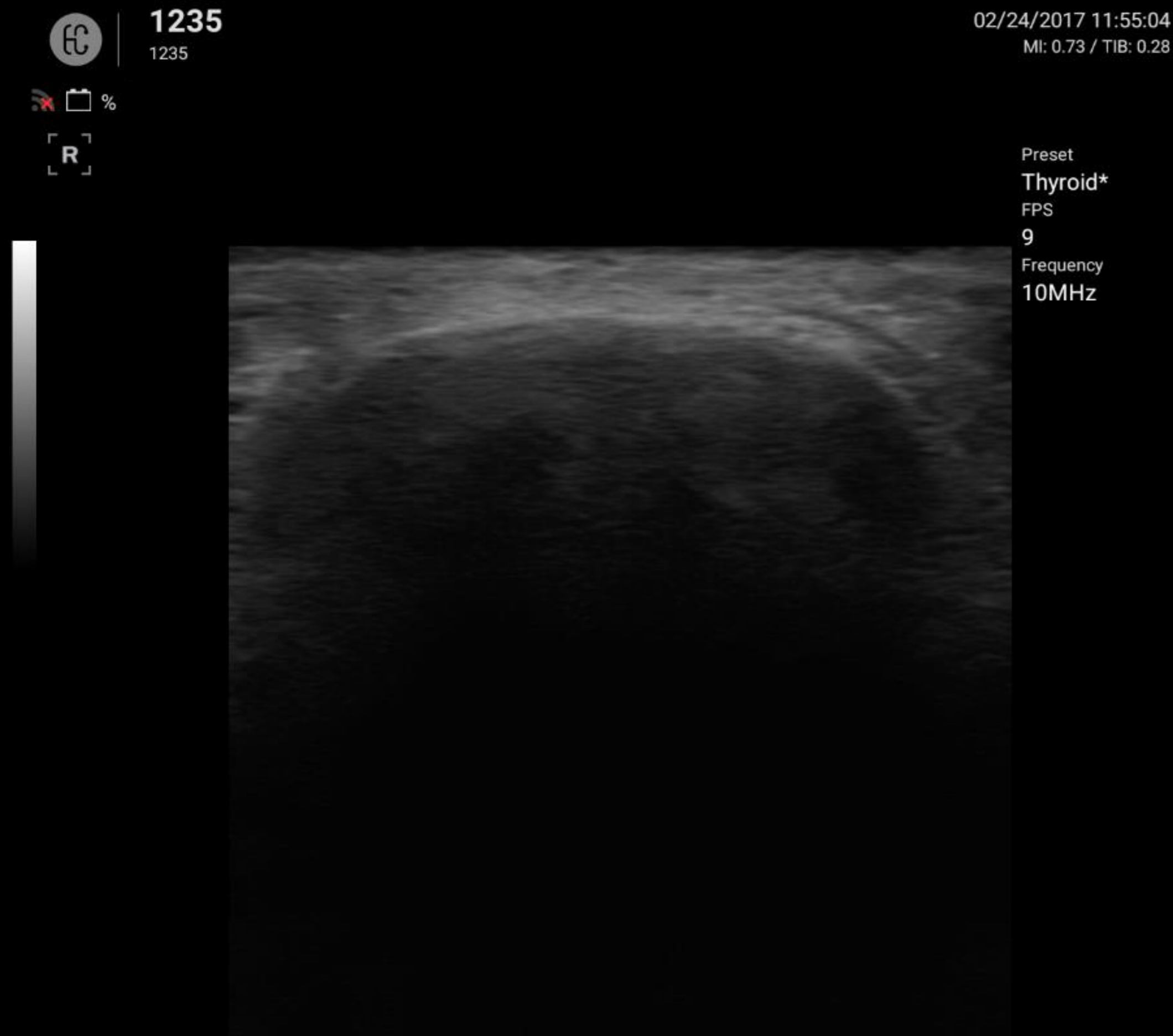
02/08/2017 11:01:24 오전
Healcerion | Unknown
MI:0.82 / TIB:0.33

Preset
Thyroid
FPS
0
Frequency
10 Mhz

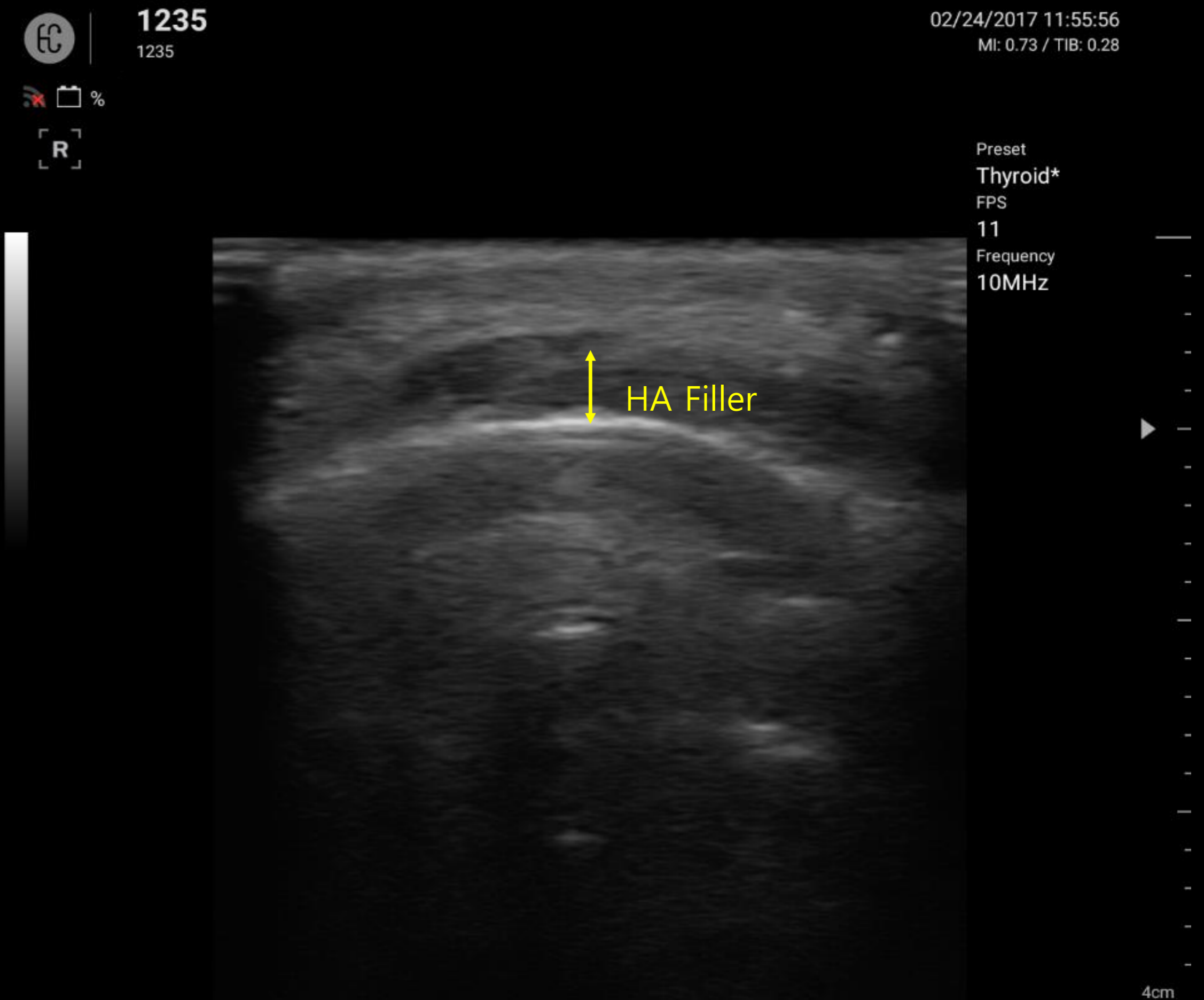
R



Aesthetic Procedure



Before filler injection (tip of the chin)



After filler injection (tip of the chin)

Aesthetic Procedure

EC 1235
1235

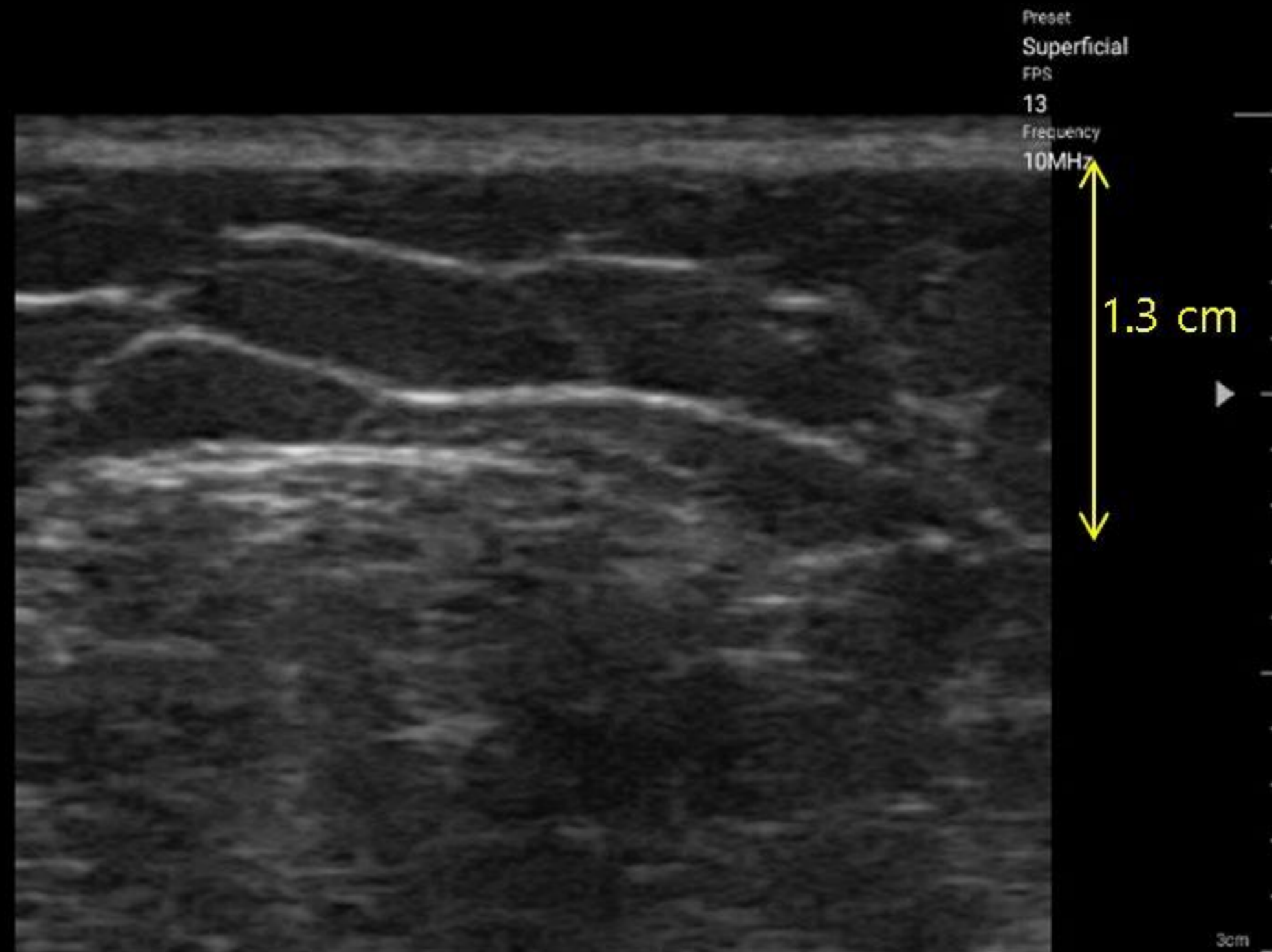


02/24/2017 11:55:56
MI: 0.73 / TIB: 0.28

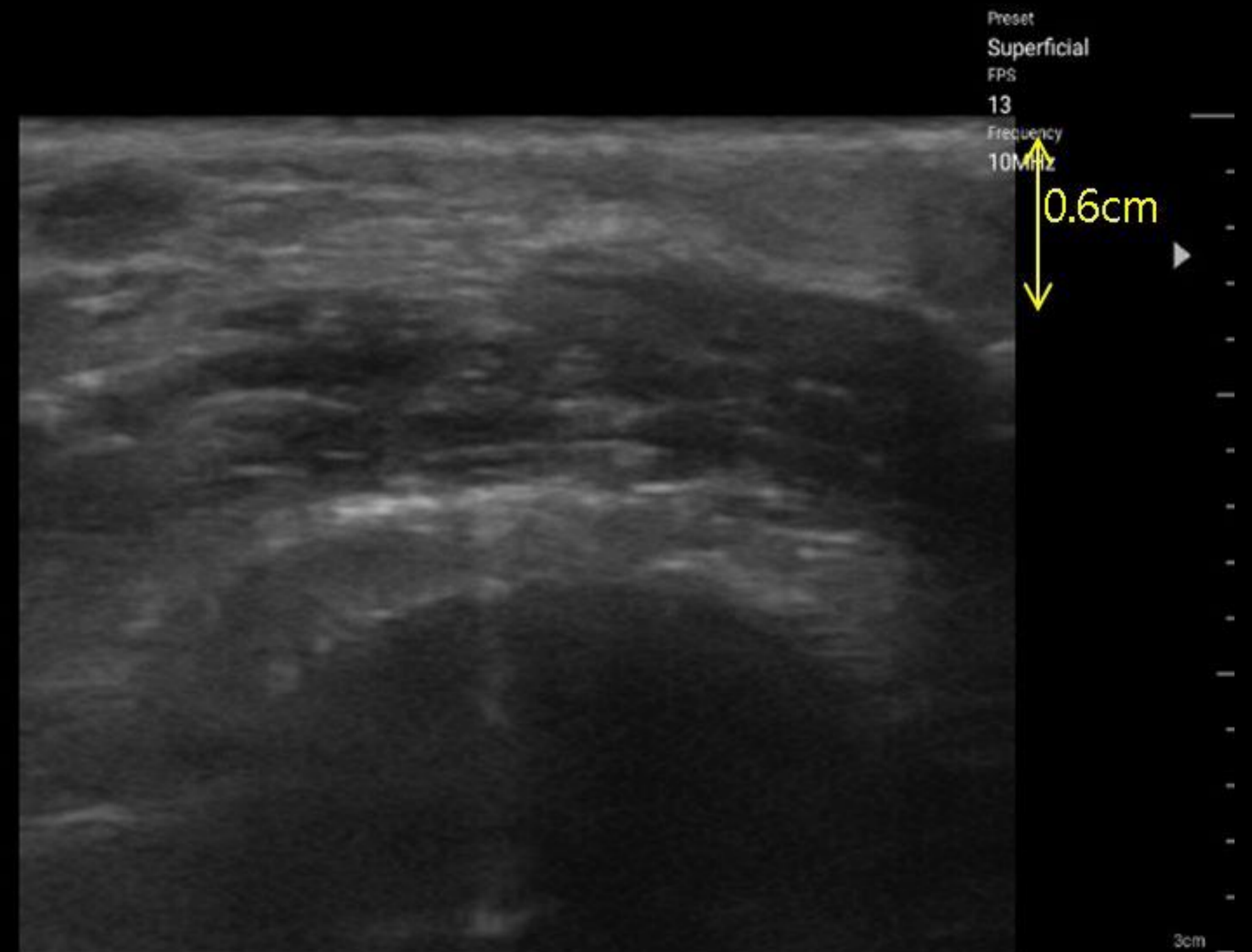
EC 1235
1235



02/24/2017 11:55:56
MI: 0.73 / TIB: 0.28



Before liposuction (Rt. Upper arm)



After liposuction (Rt. Upper arm)

Pediatric

Pediatric



42%

R

10/26/2017 10:57:50
HC | --
MI:0.73 / TIB:0.28

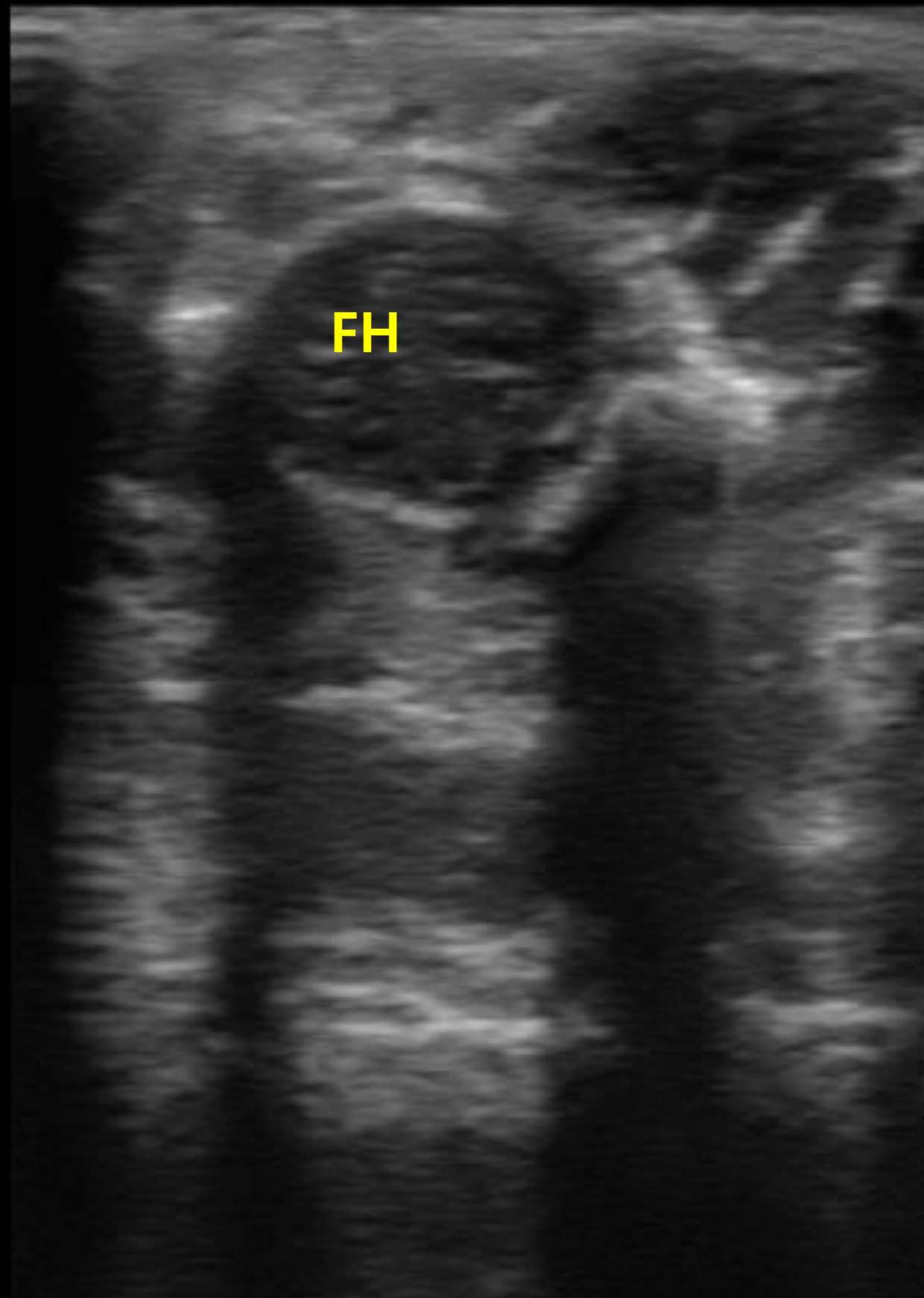


2017/10/26 07:45:33 오전
HC | Unknown
MI:0.73 / TIB:0.28

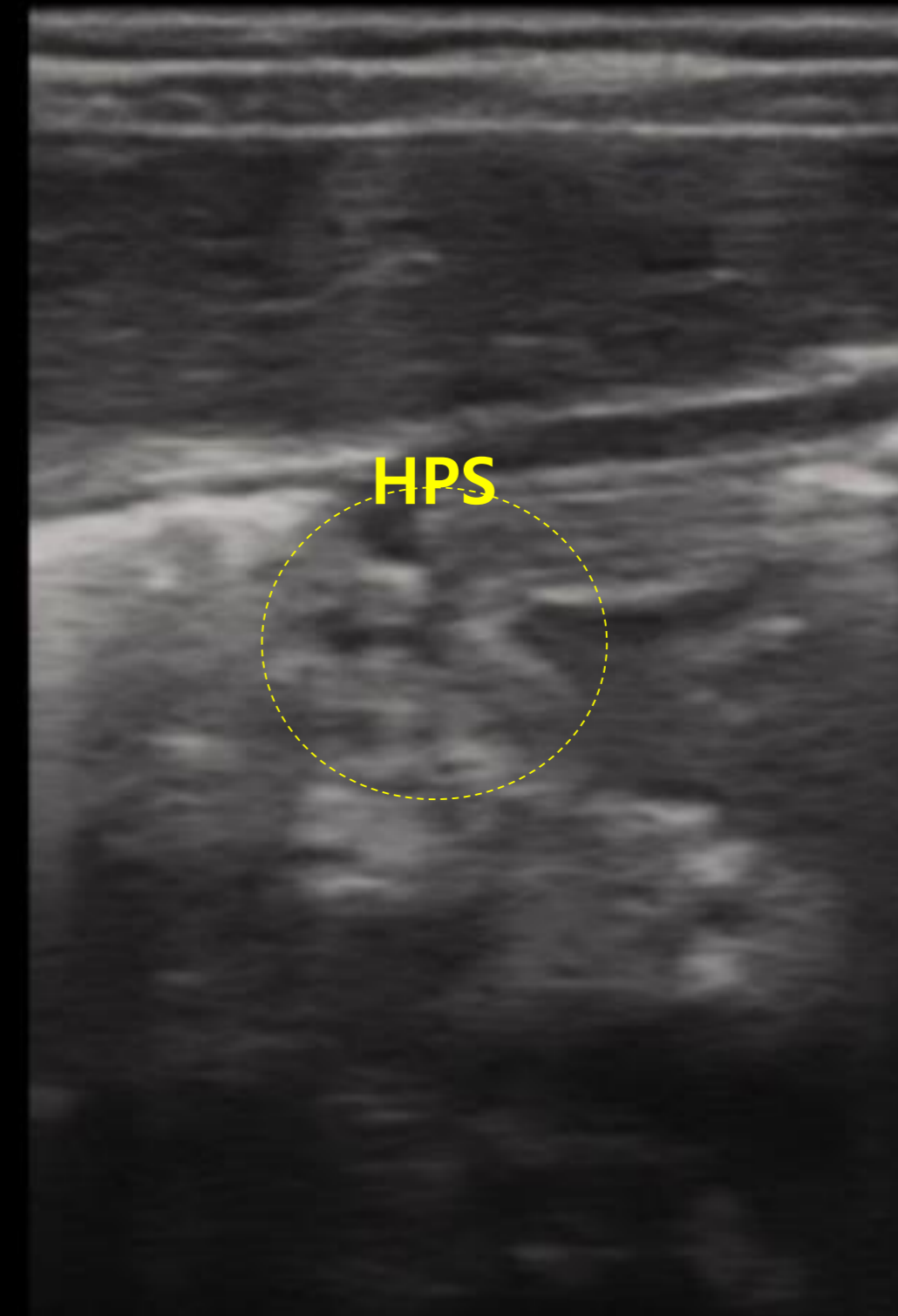
Preset
MSK
FPS
--
Frequency
10MHz

R

Preset
MSK
FPS
0
Frequency
10.0 MHz



Femoral head

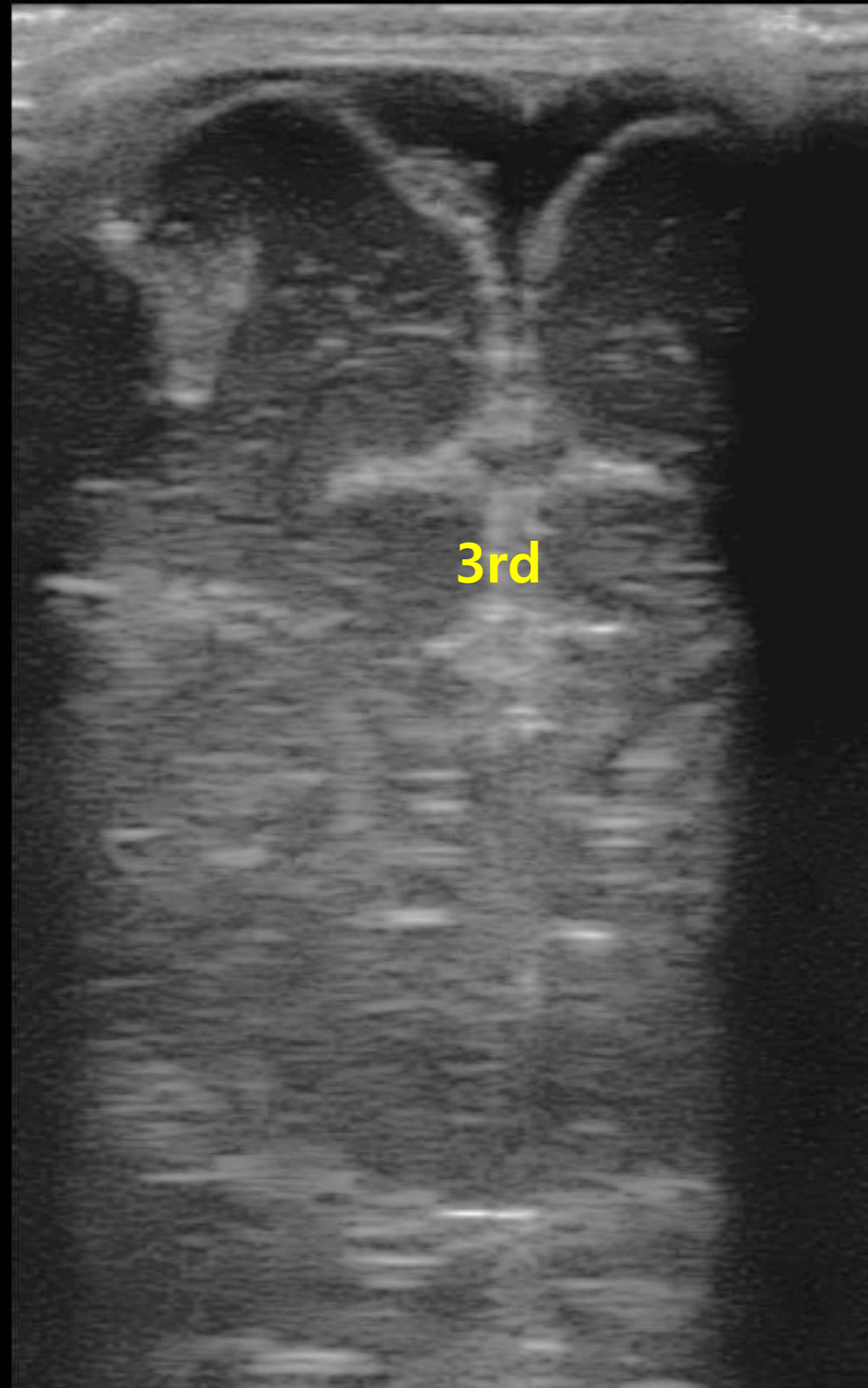


Pylos

Pediatric



42%



Fontanel

10/24/2017 14:58:09
HC | --
MI:0.73 / TIB:0.28



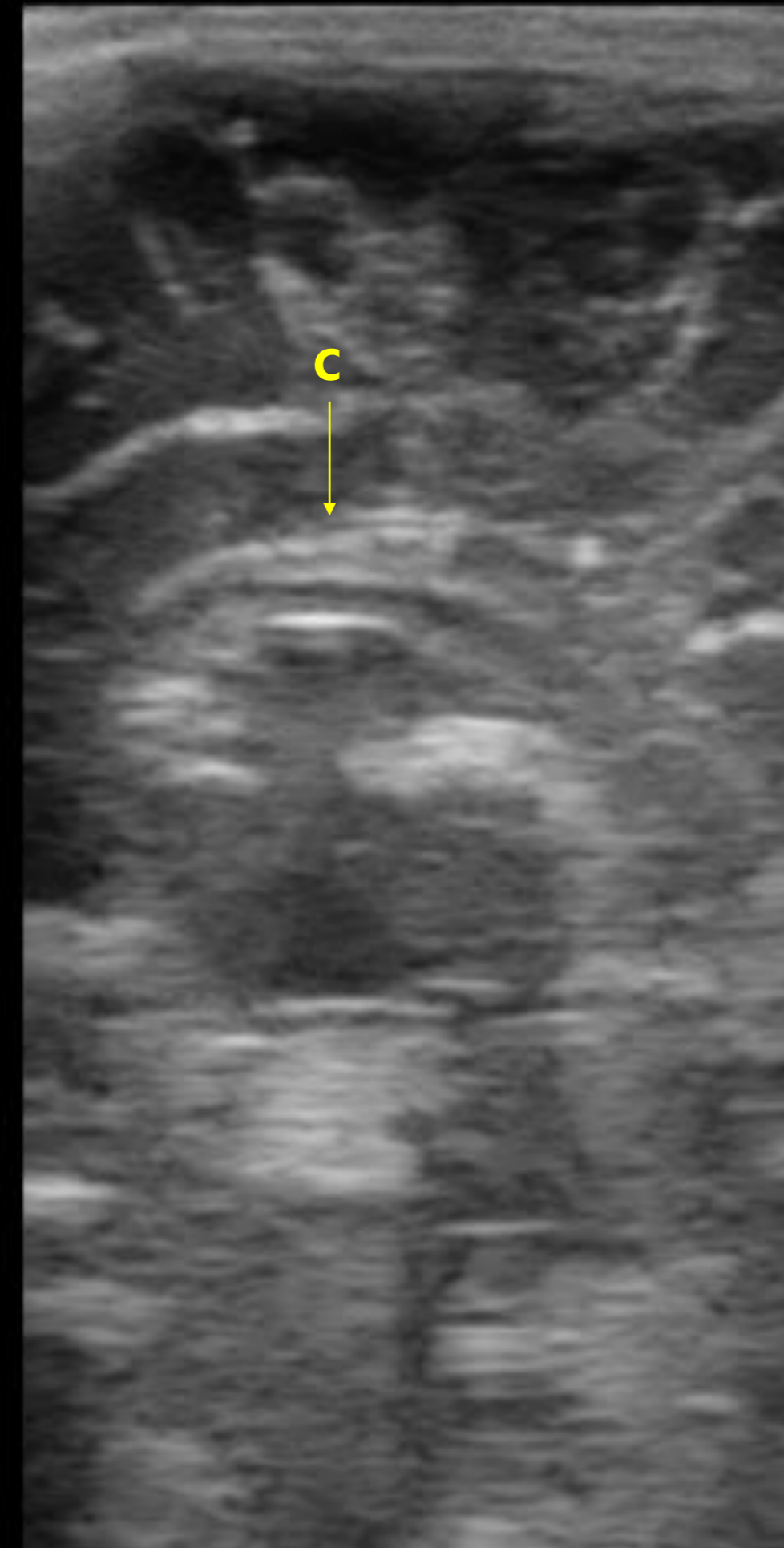
42%



Preset

FPS

Frequency
10MHz



Corpus callosom

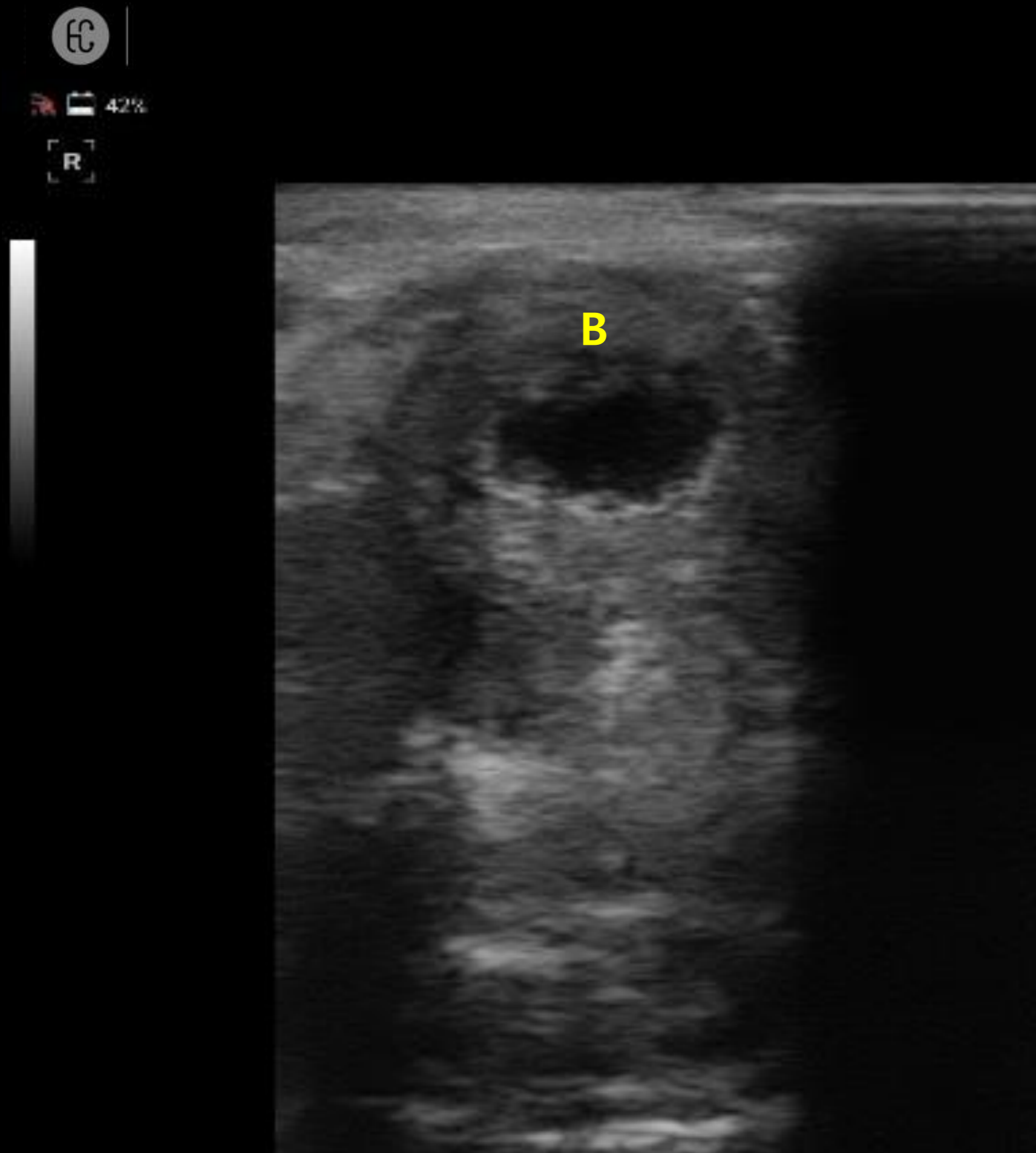
10/24/2017 14:58:09
HC | --
MI:0.73 / TIB:0.28

Preset

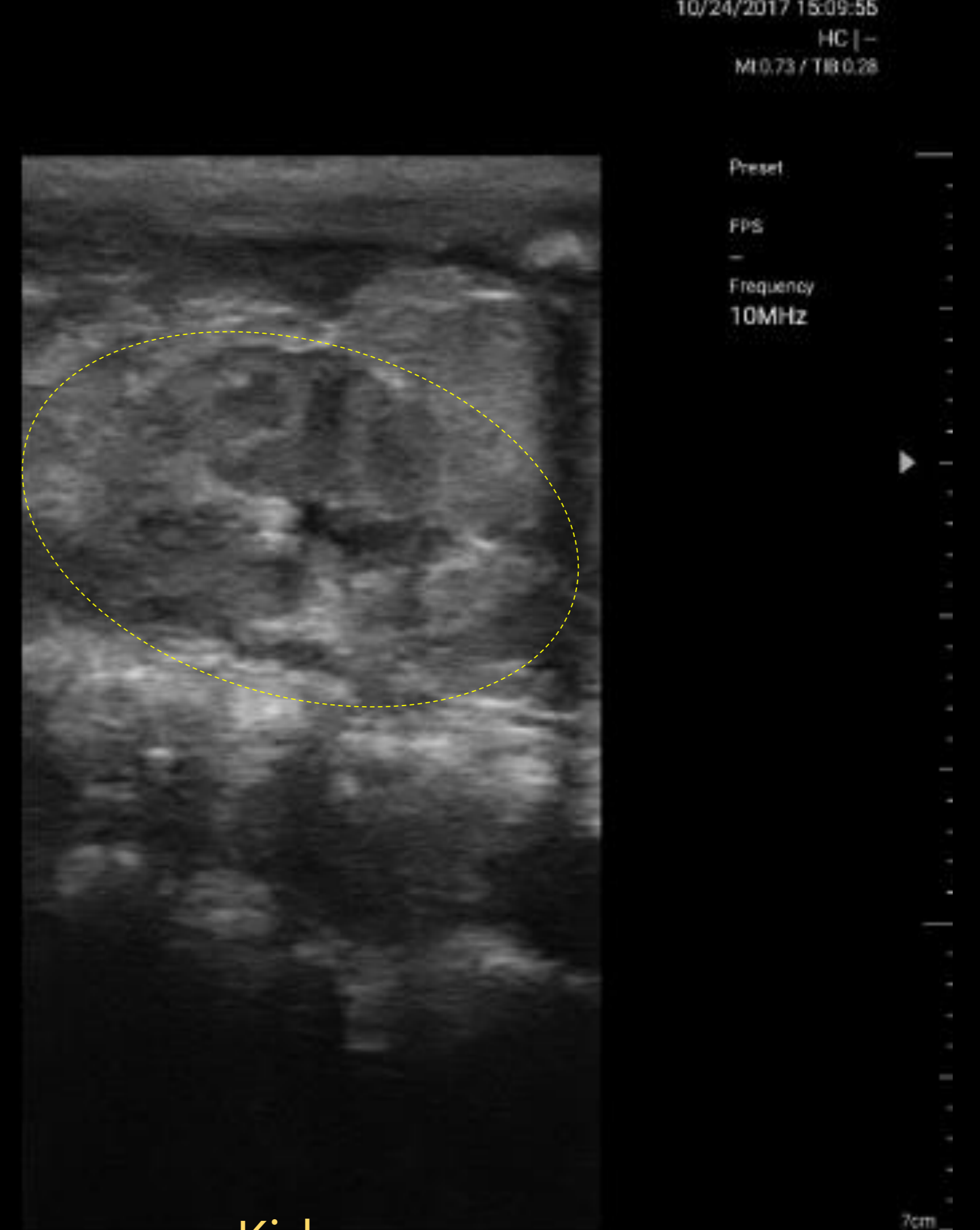

FPS

Frequency
10MHz

Pediatric



Post voiding Bladder



Kidney

7cm

Thank you